

Diseases of Amphibians

Christine L. Densmore and David Earl Green

Abstract

The development and refinement of amphibian medicine comprise an ongoing science that reflects the unique life history of these animals and our growing knowledge of amphibian diseases. Amphibians are notoriously fastidious in terms of captive care requirements, and the majority of diseases of amphibians maintained in captivity will relate directly or indirectly to husbandry and management. Investigators have described many infectious and noninfectious diseases that occur among various species of captive and wild amphibians, and there is considerable overlap in the diseases of captive versus free-ranging populations. In this article, some of the more commonly reported infectious and noninfectious diseases as well as their etiological agents and causative factors are reviewed. Some of the more common amphibian diseases with bacterial etiologies include bacterial dermatosepticemia or “red leg syndrome,” flavobacteriosis, mycobacteriosis, and chlamydiosis. The most common viral diseases of amphibians are caused by the ranaviruses, which have an impact on many species of anurans and caudates. Mycotic and mycotic-like organisms cause a number of diseases among amphibians, including chytridiomycosis, zygomycoses, chromomycoses, saprolegniasis, and ichthyophoniasis. Protozoan parasites of amphibians include a variety of amoeba, ciliates, flagellates, and sporozoans. Common metazoan parasites include various myxozoans, helminths (particularly trematodes and nematodes), and arthropods. Commonly encountered noninfectious disease etiologies for amphibians include neoplasia, absolute or specific nutritional deficiencies or overloads, chemical toxicities, and inadequate husbandry or environmental management.

Key Words: amphibian; anuran; caudate; disease; infection; medicine; pathogen

Christine L. Densmore, D.V.M., Ph.D., and David Earl Green, D.V.M., Diplomate ACVP, are Veterinary Medical Officers for the US Department of the Interior, US Geological Survey, at the Leetown Science Center, National Fish Health Research Laboratory, Kearneysville, WV, and the National Wildlife Health Center, Madison, WI, respectively.

Address correspondence and reprint requests to Dr. Christine Densmore, USGS-LSC, 11649 Leetown Road, Kearneysville, WV 25439, or email cdensmore@usgs.gov.

Amphibians are distinctive among animals physiologically, morphologically, and medically. Their collectively unique life histories and the considerable gaps in our knowledge concerning amphibian diseases and veterinary care make them comparatively challenging to diagnose, treat, and maintain successfully. In recent years, our knowledge has grown by leaps and bounds. This growth is due in part to the ongoing and increasingly successful maintenance of captive amphibians for culture, public display, the pet industry, and breeding programs for endangered species. This growth is also due to an increased scientific concern for the welfare of wild amphibian populations with the advent of emerging diseases like chytridiomycosis as well as alarm over the observed global declines of these animals, high malformation rates, extirpation of populations, and extinctions (Houlahan et al. 2000; Kiesecker et al. 2004). There is considerable overlap in the diseases described for captive versus free-ranging amphibians. In addition, diseases of free-ranging amphibians may have an impact on captive colonies or individuals through the introduction and use of field-collected animals or eggs. Amphibian caretakers must therefore be mindful of the pathogens and diseases that affect both captive and wild animals.

Many diseases of amphibians are closely related to diseases of other ectothermic vertebrates. The lower vertebrate classes share many pathogens, and in some instances, interclass transmission (e.g., from fish to amphibian) of some infectious agents occurs. This possibility is an important epidemiological consideration for amphibian disease, and it is essential not to overlook the potential role of other animal classes in disease pathogenesis. Veterinarians and care providers have often adapted diagnostic methods, treatment regimes, preventive measures, and many other facets of amphibian veterinary care from their use in other lower vertebrates.

As a preface to the following descriptions of amphibian diseases that include many different etiologies, it is important to note that the majority of diseases of amphibians and other lower vertebrates maintained in captivity will relate directly or indirectly to husbandry and management. In general, amphibians are notoriously fastidious in terms of captive care requirements, and the development and refinement of proper amphibian husbandry constitute an ongoing science. With this in mind, the amphibian caretaker must always look first to the animal's environment and maintenance to address matters concerning disease.

Bacterial Diseases

As is generally true of animals maintained in captivity, bacterial diseases may be problematic for captive amphibians. Bacterial infections are common consequences of other problems such as traumatic injury in unsanitary captive situations and may be secondary invaders following viral infections and mycotic skin infections such as saprolegniasis and chytridiomycosis. As with other ectothermic animals, the majority of pathogenic bacteria that affect amphibians are Gram-negative organisms, yet Gram-positive bacteria also may produce significant disease. Investigators have isolated many presumptive bacterial pathogens from diseased or dead amphibians, yet very few bacterial etiologies are supported by fulfillment of Koch's postulates. The difference is due both to the frequent association of bacteria as secondary to other disease processes and to the mistaken attribution of pathogen status for innocuous postmortem invaders.

Red Leg Syndrome (Bacterial Dermatosepticemia)

Among diseases that affect captive and wild amphibians, probably the most overdiagnosed and misdiagnosed disease is red leg syndrome. Also known as red leg disease or, more accurately, bacterial dermatosepticemia, red leg syndrome is a generalized systemic bacterial disease associated with, as the name implies, cutaneous erythema. Erythema, which occurs most often on the ventrum or extremities, is due to vasodilation, congestion, and petechial, paintbrush, or ecchymotic hemorrhages. Other clinical signs that are attributed to red leg syndrome include anorexia, swelling, edema (generalized or localized to extremities or the lymphatic sacs), coelomic effusions, and epidermal erosions, ulcers, sloughing, or necrosis. This disease also may present as sudden death, with few or no overt signs. Red leg syndrome is presumed to be a widespread disease, having been reported for >100 years in many different species of anurans and caudates in captivity and in the wild. However, it is necessary to view most reports that were published before the mid-1990s with caution because virus and fungal cultures were rarely attempted and many diagnoses of infection were not confirmed with histopathology. Historically, the most frequently implicated etiological agent is *Aeromonas hydrophila*; however, many other Gram-negative bacilli including aeromonads, pseudomonads, enterobacteria (e.g., *Citrobacter*, *Proteus*, *Salmonella*) may be involved. In addition, some Gram-positive bacteria (e.g., *Streptococcus* and *Staphylococcus*) have been linked to this syndrome (Crawshaw 1992; Mauel et al. 2002). Investigators now regard red leg syndrome as a more general term that is associated with peracute to acute bacterial septicemia, and it is no longer considered synonymous with *A. hydrophila*-associated disease.

Multiple and diverse pathogens of amphibians may present clinically or after death with signs of classical pre-

1990s red leg syndrome. Other nonbacterial pathogens that may present with similar clinical signs include ranaviruses (Cunningham et al. 1996a) and infection by *Batrachochytrium dendrobatidis* (chytridiomycosis). Because postmortem bacterial invasion of organs is a common phenomenon among aquatic vertebrates, including amphibians, and it occurs much more rapidly than in terrestrial, endothermic vertebrates, diagnosis of red leg syndrome is unreliable when it is based solely on bacterial isolation from tissues of an amphibian that died >1 to 3 hours before the necropsy. It is highly likely that this practice has historically led to considerable overdiagnosis of red leg syndrome epizootics among diseased amphibian populations. In addition, bacteria are occasionally isolated from healthy amphibians that are euthanized and promptly necropsied, and secondary dermal or dermatosystemic bacterial infections may be common sequelae to other infectious and noninfectious diseases, further obscuring the true etiology. This notion is further supported by the ubiquitous nature of many of the suspected bacterial pathogens associated with red leg syndrome, including *A. hydrophila*, and the frequent isolations of this genus of bacteria from the intestinal tract of normal, healthy-appearing captive and free-living amphibians. We recommend a full diagnostic workup that includes gross pathology and histopathology as well as microbial culture to achieve a more definitive diagnosis and avoid misdiagnosis of bacterial dermatosepticemia.

To treat red leg syndrome, we advise premortem identification of the etiological agent through diagnostic testing, including microbial culture and antibiotic sensitivity testing.¹ In general, parenteral broad-spectrum antibiotics have provided the best results. Treatment often may be impractical or unsuccessful, depending on the causative agent, chronicity of the disease, efficacy of antimicrobial treatment regimes, and presence of concurrent primary pathogens. If one uses broad spectrum antibiotics, it is important to strongly consider giving concurrent therapy with an antifungal drug to avoid overgrowth or opportunistic fungal infections and to eliminate possible concurrent mycotic infections. In captive populations, correction of poor husbandry practices to reduce stress and self-inflicted injury and to improve sanitation and other environmental conditions also may help to address additional underlying or concomitant problems.

Flavobacteriosis

Numerous reports of flavobacteriosis, or bacterial disease associated with the genus *Flavobacterium*, appear in the literature in association with both wild and captive amphibian populations, including anurans and caudates. Flavobacteria are Gram-negative yellow pigment-producing bacteria that are commonly recognized pathogens of lower vertebrates and are widely present in aquatic environments. Tay-

¹A Compendium of Drugs and Compounds Used in Amphibians appears as an appendix to this issue (Smith 2007).

lor et al. (2001) have referred to systemic flavobacteriosis as the “edema syndrome”; however, effusions into the lymphatic sacs and body cavity of amphibians may have many and varied etiologies, including ranaviral infections, other systemic bacterial infections, renal disease, lymph heart disease, and others. Clinical signs and gross findings of flavobacteriosis are nonspecific and include effusions in the lymphatic sacs, hydrocoelom, lingual or corneal edema, panophthalmitis, petechiation, and visceral congestion (Keller and Shilton 2002; Olson et al. 1992; Taylor et al. 2001). The clinical presentation of flavobacteriosis often closely resembles the presentation of bacterial dermatosepticemia. In addition, Hayes et al. (2002) have associated flavobacterial meningitis with immunosuppression related to pesticide exposure. Mortality due to flavobacteriosis among captive anuran colonies may be significant (Green et al. 1999). Pathogenic species reported in amphibians include *Flavobacterium oderans*, *Flavobacterium indologenes*, and *Flavobacterium meningosepticum* (Green et al. 1999; Olson et al. 1992). Veterinarians have made diagnoses through bacterial culture and molecular analysis (polymerase chain reaction [PCR²]) (Green et al. 1999; Mauel et al. 2002; Olson et al. 1992). Crawshaw (1992) and Hadfield and Whitaker (2005) have reported achieving the best treatment with antibiotic regimes based on antimicrobial sensitivity testing using premortem bacterial culture.

Mycobacteriosis

Bacteria of the genus *Mycobacterium* cause the disease mycobacteriosis. These bacteria are small, Gram-positive, acid-fast bacilli. Many ubiquitous species of mycobacteria are pathogenic, and these various mycobacteria may potentially infect and produce disease among all six vertebrate classes. Mycobacteriosis is not an unusual health-related problem among lower vertebrates, especially in association with captive aquatic species. Mycobacteria are commonly isolated from a number of captive amphibian species, most often from adult anurans (Green 2001). Species isolated from amphibians have included *Mycobacterium marinum*, *Mycobacterium chelonae*, *Mycobacterium fortuitum*, *Mycobacterium xenopi*, *Mycobacterium abscessus*, *Mycobacterium avium*, and *Mycobacterium szulgai* (Chai et al. 2006).

Mycobacteriosis is generally a chronic, slowly progressive disease that may present with a wide range of clinical signs and gross findings. Early signs of disease may be subtle or unapparent, and fulminate clinical signs often do not develop until the disease has become widely systemic. Chronic granulomatous inflammation is a hallmark of mycobacteriosis, and lesions may appear grossly as solitary or multifocal nodules. Affected skin frequently involves the digits and mouth and may present as miliary lesions. Inter-

nally, the disease commonly affects the liver, spleen, intestines, and mesonephros (kidney). Additional clinical signs include lethargy, poor body condition, and wasting as well as a mucopurulent nasal or oral discharge. Green (2001) has reported that misdiagnoses of “lymphosarcoma” and “transmissible lymphosarcoma” litter the published literature on amphibian mycobacteriosis. It is important to suspect this infection when granulomatous, histiocytic, lymphocytic, caseous, or pyogranulomatous nodules are found in any organ, including the skin.

Diagnosis of mycobacteriosis based on bacterial culture may be protracted, tedious, and often unsuccessful because mycobacterial organisms are very fastidious and notoriously slow growing. We and others (Gauthier et al. 2003; Maslow et al. 2002) recommend attempting cultures with Lowenstein-Jenson or Middlebrook agar culture media with cultures grown at 23, 30, and 37°C. It is feasible to obtain additional diagnostic confirmation through visualization of acid-fast bacilli present in cytological or histological specimens; however, if Gram-positive bacilli are evident in inflammatory nodules histologically and Ziehl-Neelsen acid-fast stain is inconclusive, it is then necessary to use alternative acid-fast stains such as Fite-Faraco. Identification of the mycobacterial pathogen via PCR is probably best for providing a reliable and timely diagnosis (Maslow et al. 2002). Various species of mycobacteria are zoonotic, therefore it is appropriate to take precautions when handling potentially infected animals or related biological specimens, especially if the handler is immunocompromised or has open skin wounds. As Pessier (2002) and Taylor et al. (2001) have reported, the lack of any reported effective treatment of mycobacteriosis for amphibians warrants the culling of affected animals and the thorough disinfection of holding facilities.

Chlamydiosis

Many reports of chlamydiosis appear in the literature among both wild and captive populations of anurans, including the African clawed frog (*Xenopus* sp.), Gunther’s triangle frog (*Ceratobatrachus guentheri*), the giant barred frog (*Mixophyes iteratus*) and most recently in the European common frog (*Rana temporaria*) (Berger et al. 1999; Blumer et al. 2007; Reed et al. 2000; Taylor et al. 2001; Wilcke et al. 1983). The causative agent, *Chlamydophila* sp., is a Gram-negative, coccoid, obligate intracellular pathogen (Bodetti et al. 2002). The most frequently identified species of chlamydial organisms reported to infect and cause disease in amphibians are *Chlamydophila psittaci* and *Chlamydophila pneumoniae* (Bodetti et al. 2002; Jacobson et al. 2002). In addition, Blumer et al. (2007) report subclinical infections by *Chlamydia suis* and *Chlamydophila abortus* in free-ranging European common frogs (*Rana temporaria*) and captive African clawed frogs (*Xenopus laevis*) in Switzerland.

Reported clinical signs of disease include petechiation and sloughing of skin, abdominal swelling due to hydrocoe-

²Abbreviations used in this article: ATV, *Ambystoma tigrinum* virus; Bd, *Batrachochytrium dendrobatidis*; FV-3, frog virus 3; PCR, polymerase chain reaction; TEV, tadpole edema virus.

lom, accumulation of excess fluid in lymphatic sacs, lethargy, and cutaneous depigmentation. Berger et al. (1999) have also reported and described an association with interstitial pneumonia. Based on clinical presentation, differentiation of chlamydiosis from red leg syndrome and ranaviral infections has been problematic. Internally, organs such as the liver, spleen, and kidney may have gross swelling and histological evidence of marked histiocytic or granulomatous inflammation. The liver is the organ of choice for histological examinations because it typically shows disseminated to diffuse lymphohistiocytic infiltrates with occasional scattered foci of purulent inflammation. Similar lymphohistiocytic (granulomatous) inflammation also affects the spleen, pulmonary interstitium, heart, and mesonephroi. Histological observation may reveal chlamydial intracytoplasmic basophilic inclusions in hepatocytes. Ultrastructurally, characteristic reticulate and dense elementary bodies are useful to confirm a diagnosis of chlamydiosis (Berger et al. 1999). Blumer et al. (2007) however, using very sensitive immunohistochemistry and PCR tests, found that histological changes were mostly absent in subclinically infected wild and captive frogs. In some cases, coinfection with other bacterial or fungal pathogens has complicated the diagnosis and histological findings. Useful diagnostic procedures have included cell culture, immunofluorescence, immunohistochemistry, electron microscopy, and PCR (Berger et al. 1999; Blumer et al. 2007). Recommended treatment regimes include oral administration of tetracycline-class antibiotics (Pessier 2002).

Viral Diseases

Compared with known viruses of other lower vertebrates, there are very few described pathogenic viruses that affect amphibians. However, based on increasing concern over the health status of wild amphibian populations and the increased use of amphibians for commercial purposes, research, and public display, our current knowledge of viral diseases that affect amphibian species has been expanding swiftly. Beginning in the 1960s, with the advance of cell culture technology, virology of ectothermic vertebrates developed considerably; and in recent years, with the advent of molecular diagnostic tools, identification and characterization of the viruses of lower vertebrate classes have become considerably more refined. Historically, the common development of secondary bacterial infections and misinterpretation of postmortem bacterial invasion were quite likely significant factors in the underdiagnosis of viral diseases of amphibians. Now, however, viruses are frequently isolated from captive and wild amphibians.

Ranaviruses

By far, the best described pathogenic amphibian viruses are the ranaviruses, a group composed of viruses from the genus

Ranavirus, family *Iridoviridae*. These double-stranded DNA viruses have icosahedral virions that measure 120 to 200 nm in diameter and sometimes bear an envelope derived from the host cell's cytoplasmic membrane (Essbauer and Ahne 2001). Several ranaviruses are well described and are known to affect fish, amphibians, and reptiles. Among the well-described piscine ranaviruses are epizootic hematopoietic necrosis virus (EHNV) and largemouth bass virus (LMBV). Investigators have demonstrated interclass transmission and development of disease in association with some ranaviruses (Essbauer and Ahne 2001). Virulence is generally host specific, and highly virulent ranavirus species and strains are known to affect anurans and caudates. Generally, pre- or perimetamorphic life stages are most susceptible. Ranaviruses frequently are associated with die-offs and acute population declines among wild amphibians and rarely are isolated from clinically normal individuals.

Although there is some uncertainty regarding precise taxonomic relationships among the described ranaviruses of amphibians, many are closely related antigenically and present with the same general suite of clinical signs and gross and histological abnormalities. Disease presentations vary from sudden death with few or no clinical signs to high percentages of severely affected individuals. Ranavirus transmission occurs by direct contact with infected animals and includes cannibalism among larvae, ingestion of virus, or contact with virus in water column (Johnson and Wellehan 2005). Disease is generally systemic and presents acutely with incubation ranging from a few days to 2 weeks (Wolf et al. 1969). Clinical signs may include lethargy; anorexia; abnormal body posture, abnormal swimming behavior, or buoyancy deficits; erythematous skin associated with petechial or paintbrush hemorrhage, particularly around the mouth or base of the hindlimbs; raised, vesicular, or erosive skin lesions; and focal to generalized swelling due to effusions in the lymphatic sacs (i.e., subcutis) and body cavity (Figure 1; Docherty et al. 2003; Johnson and Wellehan 2005; Wolf et al. 1969). Internally, there may be edema, enlargement, and hemorrhage or discoloration of numerous internal organs including the spleen, liver, kidney, and gastrointestinal tract. Histological changes include focal to diffuse necrosis throughout the skin and internal organs, particularly involving the liver and hematopoietic tissues. Basophilic intracytoplasmic inclusions formed by the virus may also be evident in some cells, especially in the liver (Bollinger et al. 1999). Additional clinical signs and histological evidence indicative of secondary bacterial infection are also common. We and others suspect asymptomatic carriers of ranaviruses among adults within a population (Brunner et al. 2005).

The type species of ranavirus is a sometimes devastating anuran pathogen known as frog virus 3 (FV-3²). First described in 1965, FV-3 is often highly virulent and pathogenic for a number of frog and toad species. FV-3 largely affects premetamorphic life stages, and associated mortality may be quite high. Tadpole edema virus (TEV²) is another named ranavirus. Originally isolated from diseased bull-



Figure 1 Free-living recently metamorphosed bullfrog (*Rana catesbeiana*) from New Hampshire with extensive effusion into lymphatic sacs of the body and thighs. Although virus cultures were negative, investigators suspected ranavirus infection. Several other infectious and noninfectious diseases may present with effusions in the lymphatic sacs and body cavity.

frogs in the 1960s, TEV is closely related to FV-3 (Hyatt et al. 2000) and occurs with the same clinical presentation in premetamorphic frogs and toads (Wolf et al. 1969). Ranaviruses that closely resemble FV-3 and TEV have been reported throughout the United States in association with die-offs of tadpoles and metamorphs, with mortality rates sometimes exceeding 90% (Green et al. 2002; Greer et al. 2005). Bohle iridovirus (BIV) is a ranavirus detected in anurans in Australia (Speare and Smith 1992). The virus affects both pre- and postmetamorphic life stages of anurans and experimentally infects and causes disease in the barramundi (*Lates calcarifer*), a catadromous species of fish. Docherty et al. (2003) and Jancovich et al. (1997) have associated die-offs among populations of tiger salamanders (*A. tigrinum*) in the western United States and elsewhere, with the *Ambystoma tigrinum* virus (ATV)², which primarily infects larvae. Docherty et al. (2003) have linked additional salamander die-offs among populations of spotted

salamanders (*A. maculatum*) in the eastern United States to a ranavirus that is closely related to FV-3. ATV appears to have a limited host range (western subspecies of tiger salamanders), whereas the FV-3-like ranaviruses from spotted salamanders often concurrently kill larval wood frogs (*Rana sylvatica*), larval bullfrogs (*Rana catesbeiana*), and larval green frogs (*Rana clamitans*) at the same site.

It is possible to diagnose ranavirus infection and disease through primary isolation in cell culture, molecular identification (PCR and sequencing of the major capsid protein), light and electron microscopy, or a combination of these techniques (Gould et al. 1995; Green 2001; Kattenbelt et al. 2000; Mao et al. 1996; Wolf et al. 1968). Numerous fish and amphibian cell lines are suitable for culture, but isolation must be maintained at room temperatures (< 25-28°C; Wolf et al. 1968). To date, no descriptions of treatment regimes appear in the literature; however, Johnson and Wellehan (2005) have postulated that acyclovir (Zovirax®) may have a potential clinical use in controlling disease and that endogenously produced amphibian bioactive skin secretions may be protective against ranaviruses. Ranavirus vaccines are not currently available for amphibians.

Lucke Herpesvirus and Other Viruses

Another well-described viral disease is the Lucke herpesvirus, an oncogenic virus also known as ranid herpesvirus-1 (RaHV-1). Lucke (1934) first described this disease in association with a renal carcinoma from a northern leopard frog (*Rana pipiens*). Lunger et al. (1965) reported isolating the virus from frogs with tumors and established causality between the virus and development of the carcinoma with intranuclear inclusions. Viral reproduction and histological appearance of typical intranuclear herpesviral inclusions by Lucke herpesvirus is temperature dependent, such that the virus replicates only at temperatures below 12°C. Metastasis to other organs may also occur at lower temperatures (Tweedell 1989). Currently, the only method for diagnosis of Lucke herpesvirus is through light and electron microscopy. Essbauer and Ahne (2001) reported two other disease-producing herpesviruses, ranid herpesvirus-2 and herpesvirus of *Rana dalmatina*, in frogs. The descriptions of these viruses, however, are not currently as complete.

Among free-ranging frogs, it is possible to detect an iridovirus-like virus in erythrocytes in blood smear slides and ultrastructurally, although this virus has not yet been cultured. The virus particles are unusual for their large size, measuring 300 to 370 nm from vertex to vertex compared with typical ranaviral particles, which measure 165 nm, and the enveloped viral particles are up to 450 nm in diameter. Similar iridovirus-like infections occur in the erythrocytes of fish and reptiles and were, for many years, misidentified as protozoan organisms such as *Toddia* spp. Gruia-Gray and Desser (1992) have used the name frog erythrocytic virus (FEV) to describe this type of virus. The infection is clini-

cally silent, and no gross or histological findings have been reported. Erythrocytic intracytoplasmic inclusions of three forms are reported: small (1-3 μm), single or multiple spherical eosinophilic inclusions; larger single, clear albuminoid vacuoles; and, infrequently, dense, elongate, crystalloid rectangular or trapezoidal inclusions (Green 2001).

Investigators have isolated other viruses from amphibians for which they have not yet fully determined pathogenicity or the viruses appear to be nonpathogenic for the species in question. These viruses include frog adenovirus 1 (FrAdV-1) isolated from leopard frog kidney tumors (Granoff 1989), *Crotalus* calicivirus type 1 (Cro-1) isolated from Bell's horned frogs (*Ceratophrys ornata*) in a zoological collection (Smith et al. 1986), and a number of different retroviruses isolated from various species including experimental hybrid Asian frogs and toads (Johnson and Wellehan 2005; Masahito et al. 1995).

Arboviruses, which are typically pathogenic for endothermic species and are transmitted from host to host by arthropod vectors, also may affect amphibians. Although no descriptions of arbovirus-associated disease among amphibians have appeared in the literature to date, the disease remains of concern largely due to the potential for zoonoses. Investigators have successfully demonstrated experimental infections in different species of frogs using the following viruses: West Nile virus (*Flaviviridae*; Klenk and Komar 2003); Japanese encephalitis virus (*Flaviviridae*; Kawasaki 1972), and eastern equine encephalitis virus (*Togaviridae*; Hayes et al. 1964). Additional reports include serological evidence of infections in frogs for St. Louis encephalitis virus (*Flaviviridae*; Whitney et al. 1968) and for western equine encephalitis (*Togaviridae*; Burton et al. 1966).

Mycotic Diseases

Fungi and fungal-like organisms represent relatively common pathogens of lower vertebrates, particularly in aquatic environments. In many instances, these agents are ubiquitous in nature and affect stressed, injured, or immunocompromised individuals. Some fungi are secondary or opportunistic invaders, but some are serious primary pathogens. Although historically regarded as fungal pathogens, molecular-based characterization of these organisms has considerably reorganized the associated phylogeny. Hence, many of the agents discussed in this section are now regarded as taxonomically distinct from the true fungi (Eumycota). In this article, for the sake of simplicity, we address all of these agents under the heading "mycotic disease." The list of fungal pathogens reported in association with observed lesions or mortality among amphibians is rather long, yet many of the associated diseases are not well described or have not been reported with great frequency. The following descriptions therefore represent an overview of only the more commonly reported and recurring fungal and fungal-like pathogens that affect amphibians.

Chytridiomycosis

Currently, the most significant and well-described pathogen of amphibians is a chytrid fungus, *Batrachochytrium dendrobatidis* (Bd²). Chytrids are ubiquitous, keratinophilic or chitinophilic, sporozoic fungi located in moist and aquatic environments. Various genera and species of chytrid fungi are known pathogens of plants, protists, and invertebrate animals, but Bd is the only chytrid known to infect vertebrates (Longcore et al. 1999). Berger et al. (1998) and Pessier et al. (1999) first described the disease chytridiomycosis in free-living amphibian populations in Australia and Central America during the mid-1990s. Retrospective studies have identified this pathogen in diseased amphibian specimens from other continents as early as the 1930s (Weldon et al. 2004). Since the report by Berger et al. (1998), we recognize this agent as a global threat to a broad host range of wild amphibian populations. Daszak et al. (1999) have associated chytridiomycosis with, or directly attributed it to, severe population declines, extirpations of populations, and extinctions. Almost monthly, the literature reflects additional reports of the association of chytridiomycosis with declining amphibian populations in Australia and the Americas, including areas throughout the United States. Although predominantly known as a disease of wild amphibians, chytridiomycosis is also problematic in captive populations (Mazzoni et al. 2003; Parker et al. 2002; Pessier et al. 1999).

Numerous species of amphibians are susceptible to chytridiomycosis, including some frogs, toads, and salamanders. However, the impacts of the disease appear to be far more severe for postmetamorphic anurans than for caudates and larvae. For anuran species, tadpoles are usually infected subclinically. Blaustein et al. (2005) and Parris and Baud (2004) have reported associated disease and mortality experimentally from premetamorphic life stages, but there is no reported occurrence in free-ranging tadpoles. In anuran tadpoles, chytridiomycosis is characterized by loss of black coloration of the mouth parts (i.e., oral disc consisting of tooth rows and jaw sheaths) and rounding of the cutting edges of the jaw sheaths. In postmetamorphic anurans, clinical signs reflect alteration of the epidermis and its important physiological functions, and occasionally opportunistic secondary infections. Clinical signs include lethargy, dehydration, dysecdysis, hyperemia of skin, and occasional neurological signs of abnormal posture, loss of righting reflex, and behavioral aberrancies (e.g., absence of fear when approached and captured). Clinical signs also may be subtle to absent among infected caudates but may include autonomy of the tail or dysecdysis. Additional gross findings include thickening of the skin (hyperkeratosis) associated with dysecdysis and, when secondary bacterial or other fungal infections are present, ulcers, petechiae, and ecchymoses of the skin and congestion of viscera (Daszak et al. 1999). Mortality rates may be quite high, clinical signs may be variable or minimal preceding death, and secondary epidermal infections may complicate the diagnosis.

Histologically, infections by Bd are limited entirely to keratinized epithelial cells of the skin and oral disc, and occasionally may be found in ingested molts in the lumen of the stomach of postmetamorphs. Acute infections by Bd are limited to the stratum corneum of the epidermis and may consist of scattered single chytrid thalli (sporangia) or small clusters of organisms within the cytoplasm of host cells. Initially, there is no host inflammatory reaction. In subacute and advanced infections, massive numbers of spherical to slightly ovoid intracytoplasmic thalli will be found in multiple retained layers of unshed epidermis (hyperkeratosis). Acanthosis also may be present, and the number of cell layers in the epidermis may increase greatly from a normal number (3-5) to a much larger number ($\geq 8-15$) (counting the layers of retained or unmolted stratum corneum). Most thalli will appear to be empty (clear), but some will contain indistinct basophilic material in the core, while a few others will contain multiple distinct minute basophilic roughly spherical zoospores. Bd does not form hyphae, but secondary invasion of the epidermis by water molds (Oomycetes) or higher fungi may occur, and some thalli that have discharged their zoospores may become secondarily invaded and filled with bacteria. Chytrid thalli have periodic acid-Schiff-positive walls and stain well with most argyrophilic and argentophilic (silver) stains.

It is possible to make a presumptive diagnosis of Bd infection cytologically and to confirm diagnoses by histology, immunohistochemistry, molecular identification (PCR) from pieces of skin, or in those laboratories with exceptional mycological expertise, by cultural isolation of the organism (Annis et al. 2004; Boyle et al. 2004; Pessier et al. 1999). PCR-based diagnostics are now widely available and usually are rapid and specific (Kriger et al. 2006), but we urge caution in interpreting PCR results from skin swabs of wild and group-caged amphibians because a positive result merely confirms the presence of the organism but does not confirm an infection in the individual.

Pessier (2002) has reported successful treatment of chytridiomycosis in captive anurans, which has included bath treatment with 0.01% itraconazole. Because this disease is transmissible by movement of infective zoospores, it affects a large number of amphibian species and is quite significant in scope. It is vitally important to consider isolating these infected animals and disinfecting equipment and surroundings (Johnson and Speare 2005, 2003; Johnson et al. 2003). It is also important for colony managers to consider establishing a quarantine period for all recently captured amphibians, and to use effective antifungal agents to prevent potential dissemination of the pathogen (Johnson and Speare 2003; Johnson et al. 2003).

Other Diseases Associated with Eumycota

The literature includes reports of zygomycoses among wild and captive anurans—diseases related to agents of the fungal subclass Zygomycetes. Causative agents have included

Mucor spp. and *Rhizopus* spp. (Taylor 2001). Zygomycoses have been reported to affect the Wyoming toad (*Bufo boreas*; Taylor et al. 1999), giant toad (*Bufo marinus*; Speare et al. 1994), Colorado River toad (*Bufo alvarius*; Fowler 1986), and White's treefrog (*Pelodytes caerulea*; Frank 1975). Clinical signs of zygomycosis have included lethargy and multifocal hyperemic nodules with grossly visible fungal growth on the ventral integument (Taylor et al. 1999). With development of clinical signs, the disease is generally progressive and leads to mortality in 1 to 2 weeks (Fowler 1986; Taylor et al. 1999). In some instances, zygomycosis, or mucormycosis, has occurred as a systemic disease with nodules and granulomatous inflammation in a variety of internal organs (Frank 1975; Speare et al. 1997), whereas another case presented only as external dermatitis (Taylor et al. 1999). Histologically, Speare et al. (1997) characterized an Australian form of mucormycosis associated with fungal spherules with granulomatous inflammation. Taylor et al. (1999) also reported nodules in the integument appearing histologically as fungal hyphae without any significant inflammation. Because the Zygomycetes are relatively ubiquitous in moist environments that are associated with soil and decaying material, infection and development of disease may occur secondary to a compromised immune system and to traumatic introduction through the skin, through ingestion, or through inhalation of fungal spores (Taylor et al. 2001, 1999). To date, there is no report of successful treatment.

Chromomycoses are diseases caused by pigmented fungal pathogens that include *Phialophora* spp., *Fonsecaea* spp., *Rhinocladiella* spp., and *Cladosporium* spp. (Juopperi et al. 2002) Like other fungal agents, these pathogens commonly exist in soil and dead plant matter. Transmission usually occurs through contamination of the environment, and traumatic injury to the skin may contribute to the infection (Juopperi et al. 2002). Two forms of disease, cutaneous and disseminated systemic, have been reported in a number of anuran species, in both wild and captive animals. Depending on the form of presentation, clinical signs of disease have included anorexia, weight loss, ulcers or nodules in the skin, and swelling and lesions of internal organs including the spleen, liver, and kidney (Taylor et al. 2001). Histologically, pigmented (dematiaceous) fungi may be found within cellular or caseous granulomas with sclerotic bodies only (chromoblastomycosis) or with pigmented hyphae and sclerotic bodies (chromomycosis). The disseminated systemic form of infection usually presents with pigmented hyphae that invade multiple organs and tissues with mild cell necrosis and minimal inflammatory cell response (Cicmanec et al. 1973; Juopperi et al. 2002). It is possible to appreciate the pigmentation of the fungi culturally, grossly, and histologically. Because it is not possible to distinguish the numerous genera of dematiaceous fungi in histological sections, we recommend cultures and identification. No documented cases of amphibians surviving chromomycosis are available, therefore no reports of successful treatment regimes appear in the literature to date. Because

of the pathogen's association with soil substrate and cutaneous injury, husbandry practices that minimize these causal factors will help prevent disease.

Saprolegniasis

A common infectious disease of aquatic lower vertebrates is saprolegniasis, which is caused by water molds such as *Saprolegnia* spp. and similar agents (e.g., *Achlya* and *Leptolegnia*). Because these organisms are ubiquitous in aquatic environments worldwide, they are frequently involved in secondary superficial infections of aquatic anurans and caudates. Water molds also commonly infect fishes, and interclass transmission of *Saprolegnia* may occur from fish to amphibians (Kiesecker et al. 2001).

Saprolegniasis may have its greatest impact on amphibian eggs, resulting in highly variable mortality levels depending on environmental factors and overall condition (or fertility) of the eggs. On occasion, saprolegniasis may produce significant egg mortality (Blaustein et al. 1994). However, water molds also commonly invade eggs after death, so it may be difficult to determine whether these organisms represent a causative factor in an egg mortality event. In affected eggs, the capsules may appear to have a thin layer of white fuzz over the surface. Fungal growth is usually white to pale gray but may vary in coloration depending on host, duration of infection, species of mold, and water quality, including suspended particulate matter in the water.

Water molds may also be primary skin or oral pathogens among larval amphibians. In general, a sustained low-level chronic mortality is the most common presentation, and often an underlying causal factor such as traumatic injury or an infectious agent may also be apparent. Clinical signs of saprolegniasis in larval amphibians include the external appearance of fungal colonies that appear fluffy or cotton-like in texture (Figure 2). Erythematous or ulcerated skin may also be visible. Although infections generally affect the tail, hindlimbs, gills, and oral mucous membranes without becoming systemic, lesions sometimes deeply penetrate and involve underlying tissues. In salamanders, additional signs have included anorexia, weight loss, lethargy, vomiting, and respiratory distress (Frye and Gillespie 1989). Death may result in severe cases, presumably from osmoregulatory impairment. Examination of fungal-infected tissues or lesions by wet mounts often reveals mats of aseptate, sparsely branching fungal filaments. Histologically, fungal filaments and zoospores are evident in lesions, although stain affinity (hematoxylin and eosin, periodic acid-Schiff) may be poor (Green 2001). Inflammatory response is generally minimal, but lesions may show evidence of erosion or ulceration, necrosis, and edema, depending on the severity. It is possible to diagnose saprolegniasis presumptively through observation alone, but a definitive diagnosis is dependent on histology, culture of the water mold, or molecular confirmation. Descriptions of various effective therapeutic regimens appear in the literature, including bath treatment with



Figure 2 Severe cutaneous saprolegniasis on the right fore limb of a hellbender (*Cryptobranchus alleganiensis*) from a zoo. Note the grossly visible colonies of the water mold.

antifungal agents such as benzalkonium chloride, copper sulfate, or potassium permanganate (Taylor et al. 2001).

Mesomycetozoans

Mesomycetozoans are members of an unusual clade of eukaryotic protists that exist phylogenetically near the animal-fungal divergence. Multiple mesomycetozoan genera, including *Amphibiothecum* (formerly *Dermosporidium*), *Amphibiocystidium*, and *Ichthyophonus*, are known pathogens of amphibians. Nomenclature changes based on molecular characterization of the mesomycetozoans is ongoing, therefore many of these organisms are in the process of being taxonomically reorganized (Feldman et al. 2005). Recent information supports the designation of the genera *Amphibiothecum* and *Amphibiocystidium* to include amphibian pathogens formerly in the genera *Dermocystidium*, *Dermosporidium*, and *Dermomycooides* (Pascolini et al. 2003).

Various species of *Amphibiocystidium* and *Amphibiothecum* are known to affect a variety of anurans including bufonids, ranids, and hylids. The organisms are spore-forming pathogens that occur in cysts, which are typically located in the ventral dermis. The infections are generally self-limiting and nonlethal, healing within 4 to 8 weeks of the development of clinical signs. Grossly, infections appear as small (≥ 1 cm) multifocal nodules or pustules, sometimes associated with an exudate. Microscopic examination of skin nodules reveals the presence of the characteristic

encysted spores that contain large cytoplasmic vacuoles. There is no established treatment beyond standard supportive care.

The mesomycetozoan *Ichthyophonus* spp. affects many species of fishes and amphibians although it is best known as a pathogen of marine fishes. Among amphibians, it has produced disease in newts, mole salamanders, ranid frogs, and pseudacrid frogs and has affected both pre- and post-metamorphic life stages almost exclusively in the eastern half of the United States. Clinically, ichthyophoniasis appears as swelling of muscles in the caudal region including tail, rump, and thighs. Especially in tadpoles, these changes are nodular. Although not commonly a lethal infection, debilitation and emaciation may lead to mortality, especially among adult frogs and newts. Diagnoses have been made through identification of the characteristic large circular or ovoid organisms within skeletal muscle cells in cytological or histological specimens. To date, there is no report of a successful treatment regime for amphibians.

Protozoan Parasites

A wide variety of protozoan organisms occur in captive and wild amphibians. Many intestinal protozoa are commensals and do not induce disease. As for other captive domestic animals, the decision to treat the amphibian patient for a given protozoan parasite must depend not only on the type of protozoa identified but also, more crucially, on the numbers of parasites encountered, the presence or absence of lesions, and the general condition of the host. The diversity of protozoans in or on amphibian species is too great to provide a comprehensive assessment here of the effects of each. Hence, the following descriptions provide a general overview of the more commonly observed protozoan parasites and related diseases.

Amoeba, Ciliates, and Flagellates

Amoebae are known to occur internally, most often in the gastrointestinal tract, liver, or kidney. Amoebiasis is known to occur in stressed amphibians and is often associated with the genera *Entamoeba* (Wright 2006). Gastrointestinal presentations are most common, and signs of amoebiasis include anorexia, weight loss, diarrhea, blood in the feces, and dehydration. Dissemination to the liver or kidney may also occur (Poynton and Whitaker 2001). It is possible to make a presumptive diagnosis of amoebiasis through positive identification of amoeba in fecal samples or cloacal wash specimens from diseased animals. Definitive diagnosis generally requires histological confirmation of invasive amoeba within tissues (Poynton and Whitaker 2001). Treatment involves supportive therapy to counter dehydration and gastrointestinal compromise as well as oral or bath administration of antiamoeboid drugs such as metronidazole (Wright 2006).

Ciliates, opalinids, and flagellates are commonly found in the gastrointestinal tract and on the skin of amphibians, and the majority of these organisms are commensal and nonproblematic. The ciliate *Tetrahymena*, while a frequent gastrointestinal commensal in many amphibians, has been problematic and has contributed to mortality among salamanders, including eggs and embryos (Pessier 2002). Trichodinids may parasitize the external surfaces or urinary bladders of amphibians, and heavy parasite loads may be associated with clinical disease (Poynton and Whitaker 2001). Flagellates such as the dinoflagellate genera *Piscinoodinium* or the kinetoplastid flagellate *Ichthyoboda* may also cause serious skin or gill lesions if present in high numbers (Poynton and Whitaker 2001). Hemoflagellates are also not uncommon and are generally nonpathogenic, although some types are associated with clinical disease. A few species of trypanosomes are known pathogens of various amphibians (Wright 2006). Clinical signs and lesions associated with anemia occur in trypanosomiasis, including anorexia, lethargy, pallor, splenomegaly, and splenic necrosis. Infections may be fatal. It is possible to diagnose trypanosomiasis using one of the following techniques: morphological identification of live motile parasites in a fresh unstained wet mount of blood, Wright's Giemsa-stained blood smears, impression smears of spleen or other highly vascular organs, or postmortem histopathology (Poynton and Whitaker 2001). Likewise, it is also possible to diagnose external, gastrointestinal, or urinary or other infections with ciliates, opalinids, or flagellates through positive identification of the causative agent in tissue impression smears or histopathology or, in live patients, through examinations of skin scrapings, gill clips, feces, cloacal washes, or urine specimens. For cases in which treatment is warranted, Iglauer et al. (1997) and Pessier (2002) have described many therapeutic agents including salt and formalin that have been used successfully as external baths against external protozoans. For gastrointestinal infections, oral or bath treatments with metronidazole have been effective, and antimalarial compounds have been successful in the treatment of trypanosomiasis (Poynton and Whitaker 2001). Attention to the environment and prevention of reinfection are also important considerations in treatment.

Sporozoans

Sporozoan parasites of many varieties, most commonly apicomplexans, may also be noted incidentally or in association with a diseased state. Investigators have found many genera of apicomplexans in amphibian blood, the gastrointestinal tract, and other organs or tissues with varying reports of pathogenicity. Poynton and Whitaker (2001) discuss two coccidian genera (*Eimeria* and *Isospora*) that quite commonly infect other vertebrates and are also found among amphibian species, generally as gastrointestinal fauna. Disease associated with coccidiosis is most common

in larvae, young postmetamorphs, or immunocompromised animals.

Occasionally, investigators have observed microsporidians, either as incidental findings or as causative agents of disease among wild and captive amphibians, particularly among anuran species. In general, microsporidians that parasitize amphibian hosts have a tropism for muscle, connective tissues of various organs, or oocytes. Schuetz et al. (1978) documented vertical transmission of the microsporidian, *Microsporidium schuetzi*, from ovary to eggs in the northern leopard frog (*Rana pipiens*; Schuetz et al. 1978). Other reports (Poynton and Whitaker 2001) have described three genera of microsporidians (*Microsporidium*, *Pleistophora*, and *Alloglugea*) that infect amphibians. When disease occurs, clinical signs may include wasting and poor body condition as well as white streaks in skeletal muscles. Gamble et al. (2005) have reported kyphosis, or convex curvature of the backbone, in association with *Pleistophora* infections among captive San Marcos salamanders (*Eurycea nana*). Histological or cytological examination of infected tissues reveals xenomas (large intracellular aggregates of the spores) in some genera of microsporidians. Observation of xenomas or intracellular spores is diagnostic for microsporidians. It is also possible to identify these pathogens through PCR (Gamble et al. 2005).

Only a few reports describe successful treatment of sporozoans. Although the use of coccidiostats has not been an effective treatment, Graczyk et al. (1996) and Poynton and Whitaker (2001) have described marginal success or clinical improvement with various antibiotic therapies. Poynton and Whitaker (2001) have also reported that supportive care including rehydration is often warranted.

Metazoan Parasites

Similar to the diseases caused by protozoan parasites, metazoan-induced diseases may be highly dependent on a number of host-related variables such as host age, condition, and presence of suitable alternative hosts. Many of the same types of metazoan parasites that affect fishes, including various helminths and arthropods, also affect aquatic life stages of amphibians.

Myxozoa

Myxozoan parasites are relatively common parasites of fish and amphibians, but unlike fish hosts, morbidity and mortality are uncommon in amphibians. In part, the paucity of reports of disease or death in amphibians with myxozoan infections may be due to lack of studies (reviewed by Eiras 2005). Investigators (Duncan et al. 2004; Upton et al. 1995) have found myxozoans of the genera *Chloromyxum* and *Myxidium* in the gall bladder and renal tubules of caudates and anurans, mostly with no associated lesions. In addition, Browne et al. (2002) and Eiras (2005) have identified go-

nadotropic myxozoa of the genus *Myxobolus* in anurans with varying degrees of testicular damage. In one case report, Duncan et al. (2004) described an unidentified chloromyxid in the kidneys of several Asian horned frogs (*Megophrys nasuta*) in association with nephritis and other renal lesions, and in all cases, this parasite was believed to be the cause of death. In another case, Mutschman (2004) reported that a different myxozoan of the genus *Hoferellus* causes frog kidney enlargement disease (FKED) among African hyperoliid frogs (*Afrixalus dorsalis*, *Hyperolius concolor*, *Hyperolius* sp.) imported into Germany from Africa through the pet trade. Diagnosis of myxozoan infections is based on histological or cytological observation of spores in lumen contents or infected tissue. There is no established treatment regime for amphibians.

Helminths

Many types of helminths may infect amphibians. Monogenes, also common parasites of fishes, may externally infect aquatic life stages of amphibians. Some monogenes may also reside on or in adults, generally as internal infections (Poynton and Whitaker 2001). Heavy infections are more likely to result in health problems due to traumatic injury or creation of a portal for secondary infections at the site of attachment. Diagnosis is usually made through parasite identification in skin scrapings, gill clips, or other tissue samplings. Treatment is rarely warranted but may be achieved through praziquantel or formalin baths (Poynton and Whitaker 2001).

Trematodes, otherwise known as flukes or digenes, may be the most widely recognized of the amphibian parasites. Amphibians may serve as secondary intermediate or definitive (final) hosts for trematodes. In general, disease is associated only with high numbers of trematodes encysting in, attaching to, or migrating through host tissues. Lesions generally result from trauma, compression, or displacement of normal tissue by encysted metacercariae, an intermediate life stage of trematodes. Metacercariae of the trematode *Ribeiroia* are known to induce polydactyly and other limb malformations among frogs when tadpoles are infected at specific developmental stages (Figure 3). Severe deformities may result from *Ribeiroia* infections, and this organism is believed to be the cause of many types of malformations and increased mortality among wild amphibian populations (Johnson et al. 1999). Metacercariae of the trematode *Clinostomum* affect ranids and ambystomid salamanders. The disease produces grossly visible yellowish lumps under the skin (Figure 4), and an experienced parasitologist makes a diagnosis by identifying the encysted parasites. Treatment is difficult but may be directed against the adult life stage of the parasite with repeated administration of praziquantel. Poynton and Whitaker (2001) also recommend pretreatment with corticosteroids. A highly effective way to prevent infection by metacercariae is to simply remove all aquatic snails (primary intermediate hosts) from aquariums or other closed aquatic systems.

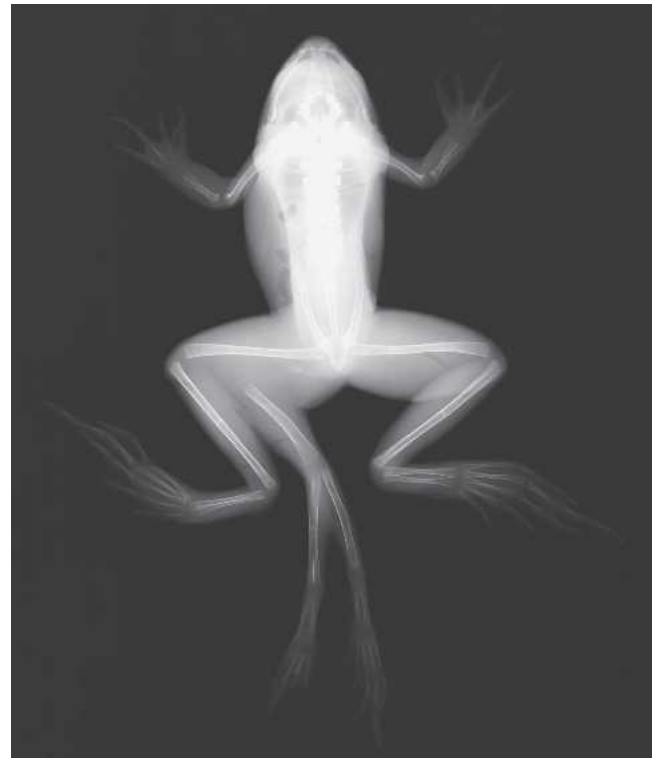
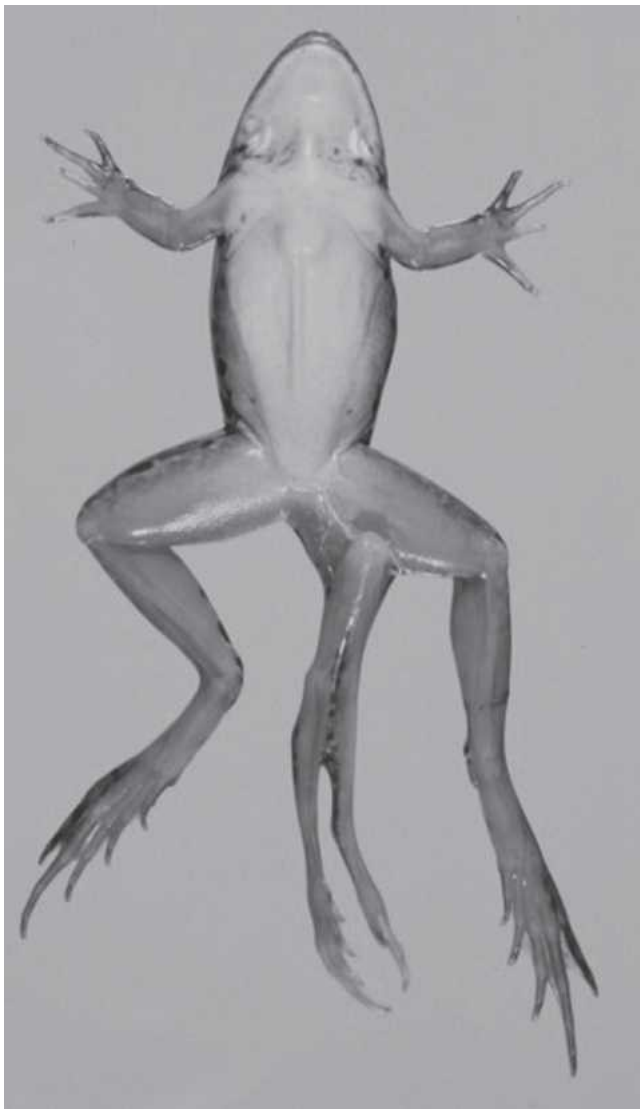

Figure 3 Free-living, recently metamorphosed northern leopard frog (*Rana pipiens*) from Wisconsin. Investigators presumptively attributed polymelia, or supernumerary limb development, to infection by metacercariae of the trematode *Ribeiroia* sp. during specific developmental stages of the tadpole. (left) Frog in dorsal recumbency. (right) Dorsoventral radiograph of this same animal, with the skeletal malformation highlighted.

Nematodes, or roundworms, are also common helminths that infect amphibians from egg to adult life stages and affect a variety of organs and tissues. Nematodes of the genus *Rhabdias* are lungworms that are problematic among captive anurans and possibly caudates. The parthenogenic adult worms cause pulmonary damage and eosinophilic pneumonia. The worm, which has a direct life cycle, produces large numbers of larvated eggs that hatch efficiently at room temperature. Some larvated eggs may hatch within the lumen of the lung or while passing through the gastrointestinal tract. The larvae actively burrow into the skin and deeper organs, and large numbers of burrowing larvae may be fatal to anurans (Williams 1960). Larvae are free in the lymphatic sacs and body cavity, and they appear histologically in nearly all organs. Hence, it is essential to promptly

quarantine all recently captured postmetamorphic anurans and salamanders (or amphibians from sources of uncertain health status) and then to either test for this parasite or to promptly treat the animal with an appropriate anthelmintic.

Other nematodes may be problematic, particularly among captive amphibian populations. Patterson-Kane et al. (2001) have reported a nematode of the genus *Strongyloides* in association with a protein-losing enteropathy and death in a captive Cope's gray tree frog (*Hyla chrysoscelis*). Although *Strongyloides* nematodes are well known intestinal parasites among vertebrates, this was the first report of enteric strongyloidiasis with associated lesions in an amphibian.

Pseudocapillaroides xenopi is an important capillarid parasite of the dorsal skin of captive adult African clawed

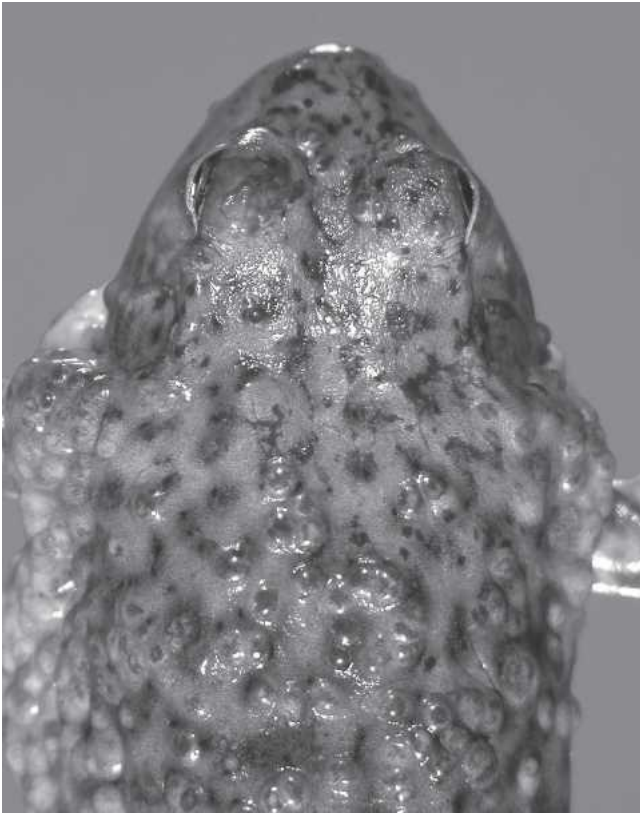


Figure 4 Free-living bullfrog (*Rana catesbeiana*) from Arizona with numerous encysted metacercariae of the trematode *Clinostomum*.

frogs (mostly *X. laevis*). This intraepidermal parasite has a direct life cycle, hence, serious and life-threatening infections may develop in colony frogs (Cunningham et al. 1996b; Stephens et al. 1987). Clinical signs in affected frogs may include lethargy, mild loss of dorsal skin pigmentation, roughened and frayed dorsal skin, erythema, and occasionally skin ulcers. Mild infections, however, may be clinically silent. Grossly, the adult parasites are present in the epidermis, and their burrowing activities may result in life-threatening secondary bacterial and fungal infections. Histologically, the adult parasites typically occur only in the epidermis, where they leave multiple empty burrow holes. The inflammatory cell response is quite variable but often is associated with secondary infections. Eggs are typical of capillarids; they are ovoid, pigmented (brownish), have bipolar plugs, and are larvated.

Diagnostic methods are dependent on the life history of the nematode in question; however, methods may include fecal examination, transtracheal washes, skin scrapings, or blood samplings, all followed by identification of ova, larvae, or adult parasites. It is possible to diagnose rhabdiasis and strongyloidiasis by detecting typical strongyloid-size larvated eggs in direct smears of fresh amphibian feces or fecal flotation tests. Detection of the typical eggs of *P. xenopi* in one or more of the following areas is sufficient for

a diagnosis and initiation of anthelmintic treatments: in skin scrapings, in skin molts, histologically in burrow holes, within sectioned adult female worms, or in aquarium sediments. It is also necessary to thoroughly clean or change aquariums and filters to remove eggs and prevent reinfection in the animal colony.

Treatment includes administration of various anthelmintic regimes, including oral or bath treatments with fenbendazole, levamisole, thiabendazole, or ivermectin (Hadfield and Whitaker 2005; Iglauer et al. 1997; Pessier 2002; Wright 2006). Establishment of good hygiene practices to minimize the source of infection may be of great benefit when trying to control disease related to the nematodes with direct life cycles such as *Rhabdias*, *Strongyloides*, or *Pseudocapillaroides*.

Filarid nematodes, which mosquitoes transmit, typically reside only in wild-caught adult amphibians or outdoor amphibian colonies exposed to vectors. Clinical signs usually are vague, but it is occasionally possible to detect those species of filarids whose adults occupy the lymphatic sacs as serpentine nodules or ridges under the skin. Diagnostic methods for filarids include examinations of stained blood smear slides or unstained wet-mount drops of blood for microfilaria. If adult filarids are visible in the lymphatic sacs, we advise removing the worms through a skin incision for identification.

Other helminths reported to infect amphibians and occasionally produce disease include cestodes, acanthocephalans, and hirudineans. Cestodes, or tapeworms, are not commonly isolated from or problematic in amphibian species, but they may produce significant gastrointestinal lesions, gastrointestinal obstruction, and death in heavy infections (Wright 2006). Diagnosis may be made through fecal examination or examination of the intestines at necropsy. Treatment is through oral administration of praziquantel (Poynton and Whitaker 2001). Acanthocephalans, or thorny-headed worms, may produce lesions as encysted juveniles or as adults embedded in the intestines of amphibians. Diagnosis is made through fecal examination, and there is no established treatment. Hirudineans, or leeches, affect amphibians as they do other vertebrates by attaching to and feeding on the blood of the host, either externally or internally. Leeches are detrimental not only because of the related tissue trauma but also because they may act as vectors for infectious diseases. It is possible to diagnose externally attached leeches through gross examination and to manually remove them from the amphibian host (Pessier 2002).

Arthropods

Also potential vectors of infectious disease, various arthropods may act as parasites for amphibians. Small crustaceans known to parasitize fishes may also affect aquatic life stages of amphibians. Such parasites include the fish louse (*Argulus*) and the parasitic “anchor worm” copepod *Lernaea* (Crawshaw 1992). These organisms attach to skin or gill

tissue to feed on the host, and the severity and significance of traumatic lesions and associated effects are dependent on parasite load. Diagnosis is made through gross observation, and treatment through therapeutic baths with salt or ivermectin may be warranted (Pessier 2002).

Mites and ticks may also be ectoparasites of postmetamorphic amphibians. Most notably problematic among these organisms are the trombiculid mites. Larval trombiculids, also known as chiggers, parasitize the skin of their hosts and may be associated with extensive red-orange vesicular skin lesions among wild anurans and caudates (Sladky et al. 2000). Amphibian chiggers differ from most other chiggers in that the nymphal stage embeds and encysts in the skin. *Hannemania* spp. are the most common chiggers of amphibians in the United States, whereas other genera may predominate on other continents. *Hannemania* may remain encysted in the host for several months, usually overwintering in the skin with the hibernating amphibian. It is possible to diagnose chigger infestations by gently lancing one or more cysts and gently teasing free the orange nymphs. For the treatment of captive amphibians, Poynton and Whitaker (2001) and Sladky et al. (2000) recommend long-term oral or topical ivermectin coupled with environmental management.

Of the insects, the larval stages of dipterid flies (maggots) may be parasitic for different life stages of amphibians. Maggots are far more problematic among wild than among captive-held specimens. Menin and Giaretta (2003) have noted the occasional occurrence of maggots on and between eggs in egg masses of ranids and salamanders, and have documented the maggots' consumption of eggs and embryos. Maggots may also parasitize adults, feeding on tissues and debilitating or killing a host (Duellman and Trueb 1986; Pounds and Crump 1987). Diagnoses are made from identification of the maggot or the fly. Treatment may require surgical removal of the parasites and management of the associated wounds. Topical or bath application of antiparasitological agents, including levamisole or ivermectin, may help to clear the infestation (Wright 2006).

Neoplasia

Neoplastic diseases, although reported and well documented among amphibians, are not especially common. Descriptions have included both benign and malignant neoplasms that represent numerous tissues of origin among anurans and caudates. A complete review of these multiple and varied forms of amphibian neoplasia is beyond the scope of this article, therefore we direct interested readers to Green and Harshbarger's (2001) comprehensive review of spontaneous neoplasia in amphibians, and the Registry of Tumors in Lower Animals' extensive archive of reported neoplasms of amphibians and other lower vertebrates (<http://www.pathology-registry.org>). Although the majority of documented neoplasms have come from captive amphibians, neoplasms have also been described among wild populations, including reported epidemics of neoplastic disease.

Green and Harshbarger (2001) and Stacy and Parker (2004) have reported neoplasms from a number of cell types that have affected many different organs of amphibians.

Probably the two most commonly reported amphibian neoplastic syndromes are the Lucke renal carcinoma of northern leopard frogs and the squamous cell papilloma of the Japanese fire-bellied newt (*Cynops pyrrhogaster*) and other caudates. The Lucke renal carcinoma is associated with a herpesvirus, which has been reported among wild populations of the northern leopard frog (and captive specimens taken from the wild) from the northern United States and Canada over the past 70 years (Green and Harshbarger 2001). This neoplasm is malignant and tends to metastasize, therefore prognosis is generally poor. By contrast, the squamous cell papilloma is a benign neoplasm of the integument, which often regresses spontaneously (Pfeiffer et al. 1979). Less frequently, this neoplasm continues to develop, produces significant disease, and either directly or indirectly causes death. There are reports of this neoplasm among caudates and anurans and, most frequently, among Japanese fire-bellied newts, barred tiger salamanders (*Ambystoma mavortium*), and Tohoku salamanders (*Hynobius lichenatus*) (Stacy and Parker 2004). Squamous cell papillomata appear grossly as well-demarcated wart-like lesions, which may be located anywhere on the skin.

By definition, neoplasia requires a histologically definitive diagnosis from tissue samples obtained from biopsy or necropsy for two primary reasons: (1) There are many causes of lumps and bumps among amphibians, and a diagnosis of neoplasm based solely on gross clinical appearance is often inaccurate. (2) Granulomatous inflammatory responses, encysted parasites, and infections by mesomycozoa are common causes of nonneoplastic tumors, which historically have been mistaken for neoplasms with some regularity (Green and Harshbarger 2001). Treatment options and prognosis vary considerably depending on the type of neoplasm and progression of the disease.

Nutritional Diseases

It is often difficult to successfully maintain amphibians in captivity, frequently due to their fastidious and changing nutritional requirements over different life stages. Amphibians are a diverse class of animals, and little is known of nutritional requirements for many amphibian species. Additionally, diets of captive animals are often limited by the commercial availability of food. For these reasons, there are many descriptions of nutritional diseases among captive amphibians. In broad terms, these nutritional diseases result from one of two problems—dietary deficiency or dietary excess.

Dietary Deficiencies

Overall dietary deficiency that results in an insufficient caloric intake will lead to malnutrition and starvation. Often,

this occurrence is due to a poor understanding of and failure to provide for the dietary needs of a particular species and life stage. Although adult amphibians are generally carnivorous, the types and sizes of food they will accept and even the timing of feedings will vary considerably and have a significant impact on their willingness to feed. In addition, many commonly offered food items, including a variety of insects, have inadequate levels or imbalanced ratios of some essential nutrients (Barker et al. 1998). Hence, a thorough understanding of the life history and particularities of the species and life stage in question as well as the nutrient composition of the diet offered is essential to good husbandry and providing adequate nutritional support. Clinical indications of malnutrition/starvation include anorexia and may also include weight loss, dehydration, and lethargy. Cachexia that mimics starvation may be due to other systemic disease, thus determination of any other causal factors is important. Regardless of etiology, as Wright and Whitaker (2001) have described, it is often necessary to provide malnourished amphibians with nutritional supportive care through assist-feeding.

Of the specific dietary problems that affect amphibians, some of the more commonly encountered challenges are the vitamin and mineral imbalances related to metabolic bone disease. Specifically, these imbalances include the failure to ingest or adequately process vitamin D₃, calcium, or phosphorus to maintain them in the proper ratios. Elevated levels of vitamin A may also interfere with normal metabolism of vitamin D and contribute to metabolic bone disease. Most often, however, metabolic bone disease is caused by low levels of calcium or improper calcium:phosphorus ratios in the insect prey (Wright and Whitaker 2001). Many insects used as food or prey, including mealworms, waxworms, earthworms, and fruit flies, have low levels of calcium or imbalanced calcium:phosphorus ratios (Barker et al. 1998). It is possible to correct this calcium deficiency by feeding the insects calcium-rich food or by dusting the insects with a calcium-rich powder. (Note: the “exoskeleton” of insects consists of chitin, which contains negligible amounts of calcium.) Although proper absorbance of ultraviolet radiation is an important consideration in the prevention of metabolic bone disease among reptiles, this link is not as well established for amphibians.

Descriptions of metabolic bone disease in many species of amphibians are available and include anurans, caudates, and caecilians. Clinical signs that typify this syndrome are indicative of inadequate bone mineralization and may include abnormal posture and locomotion, tetany, anasarca, dropsy, subcutaneous edema, vertebral deformity, mandibular deformity, pathological fractures of long bones, and absence of radio-opaque calcium carbonate in the endolymphatic sacs. It is possible to use radiology to confirm a diagnosis by highlighting the altered bone density and other related indications such as bone deformity or pathological fractures. Treatment is often difficult, particularly in advanced cases. Treatment regimes involve dietary supplementation with calcium and vitamin D₃ or, alternatively,

topical (bath) or parenteral calcium supplementation (Hadfield and Whitaker 2005; Wright 2006). The preferred treatment regime will be largely dependent on the species and life stage in question as well as the severity of disease.

Hypovitaminosis A may be an emerging nutritional disease of concern in captive amphibians in zoos and conservation programs (Wright 2006). Amphibians do not synthesize carotenoids, including vitamin A (retinol), therefore the animals must obtain these nutrients from food items. At present, investigators are uncertain whether vitamin A is the only essential carotenoid of amphibians or whether precursors such as carotene, lycopene, phytoene, or other isoprenoids are essential in the diet. In addition to being essential for maintaining epithelial integrity and bone metabolism, carotenoids also are incorporated into xanthophores in the amphibian skin (Frost-Mason et al. 1994). Clinical signs of hypovitaminosis A in captive postmetamorphic toads include listlessness, wasting, and reduced ability to capture live prey with the tongue. Pessier et al. (2005) reported this “short tongue syndrome” in captive Wyoming toads, and since that time, other investigators have observed the syndrome in other captive amphibians (Wright 2006). The principal histological finding in affected toads was squamous metaplasia of the tongue with consequent loss of mucous cells and sticky secretions on the surface of the tongue that are necessary to apprehend live insects. Parenteral, oral, or topical (bath) treatments with vitamin A may alleviate the deficiency, but recovery time has not been reported and supportive care, including force feeding, may be necessary during treatment.

Investigators including Crawshaw (2003) and Wright and Whitaker (2001) have associated the deficiency of B vitamins in amphibians with various neurological and musculoskeletal abnormalities, including hindlimb paresis and paralysis, scoliosis, and the spindly leg syndrome in a number of anuran species maintained in captivity. In many cases, investigators suspected that leeching of the B vitamins from the diet was a causal factor that B vitamin supplementation of the water could offset. Thiamine (vitamin B₁) deficiency causes neurological dysfunction and is reported among many different vertebrate species fed diets that contain certain fishes and invertebrates rich in the enzyme thiaminase. Wright and Whitaker (2001) have reported clinical signs and lesions that include paralysis and peripheral nerve demyelination, consistent with thiamine deficiency among captive amphibians. Usually this deficiency is reversible with thiamine supplementation given topically or parenterally as treatment and as a feed additive to prevent further occurrence (Crawshaw 2003).

Dietary Excess

Captive amphibians fed diets with a surplus of energy may become obese. Like malnutrition, this phenomenon is most likely to occur in amphibians when care providers do not carefully consider specific dietary requirements and caloric

needs. Gastric overload, which results from consumption of an excessive quantity of food such as oversized prey, is a syndrome of more immediate concern with an overfed amphibian because this occurrence represents a medical emergency. The resultant overdistension of the stomach may compromise respiration and circulation, which places the animal at risk for hypovolemic shock unless it is treated immediately. Usually it is necessary to remove the food item(s) from the stomach surgically; however, in some cases, it may be possible to carefully remove the material through the mouth via forceps or endoscopy (Wright and Whitaker 2001). Similarly, gastric or intestinal impactions may present as surgical emergencies. These occurrences generally result from the ingestion of nonfood items such as cage substrate.

Generally, dietary deficiencies are more likely to occur than dietary oversupplementation with regard to specific nutrients. However, excessive dietary intake of the fat-soluble vitamins A and D has been associated with disease in situations involving high concentrations of vitamins in feed or prey. Hypervitaminosis A is principally a disease of African clawed frogs (*Xenopus* spp.) that are fed mammalian livers or whole immature rodents, both of which are rich sources of vitamin A. In these circumstances, hypervitaminosis A may play a role in the development of metabolic bone disease and cause anemia, liver damage, and chronic weight loss (Crawshaw 2003). Frye (1992) has described hypervitaminosis D₃ in the ornate horned frog (*Ceratophrys ornata*) fed goldfish high in D₃. The author noted anasarca, or generalized edema, and debilitation along with mineralization of soft tissues in this animal. Thus, when an investigator or care provider suspects hypervitaminosis, it is essential to adjust the diet accordingly to treat existing disease or to prevent recurrence.

The literature includes reports (Wright and Whitaker 2001) that describe oxalate toxicity in amphibians on diets that have contained oxalate-rich plants including spinach and kale. High dietary oxalate levels predispose some amphibian species to the development of renal calculi and associated urinary disease (Figure 5). Herbivorous aquatic life stages are most at risk. Wright and Whitaker (2001) observed this disease in captive tadpoles and frogs consuming spinach or crickets that fed on an oxalate-containing plant.

Corneal lipidosis is a relatively common ocular disorder among aged captive amphibians that has been associated with high levels of dietary cholesterol. Shilton et al. (2001) documented a correlation between high dietary cholesterol level, corneal lipid deposition, and high serum cholesterol level. Clinically, corneal lipidosis first appears as a haziness that may progress to opacity and blindness (Keller and Shilton 2002). To prevent exacerbation of this condition, it is important to modify the diet. To date, there are no reports of successful treatment.

Nutritional diseases associated with excessive vitamin and mineral supplementation may be a potential problem in tropical and neotropical captive amphibians in zoological parks and captive breeding programs. Recently, the dra-

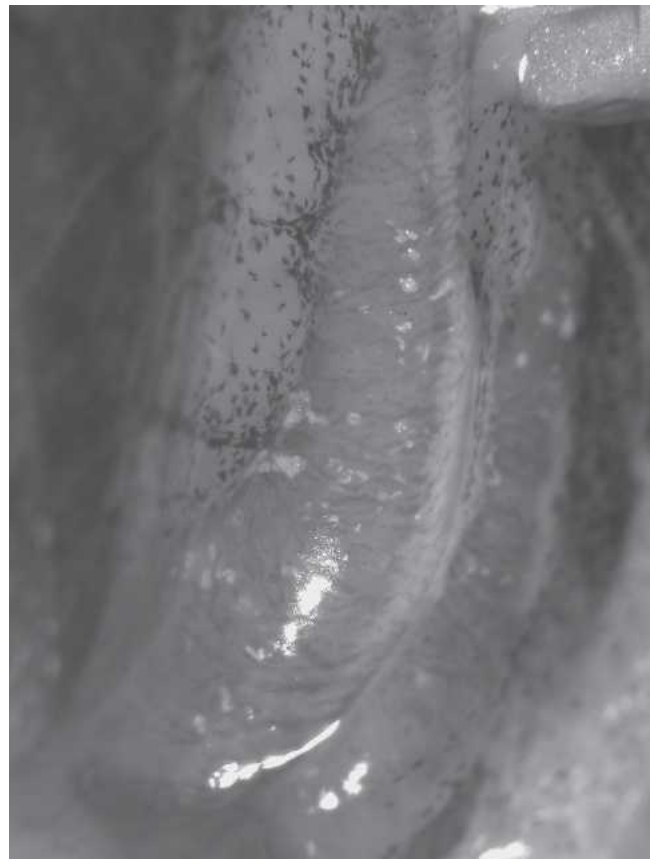

Figure 5 Relict leopard frog (*Rana onca*) from a captive breeding program with nephrosis due to oxalate toxicity. Recently metamorphosed frogs presented with marked effusions in their lymphatic sacs and coelom. Note the grossly visible multifocal white renal calculi present in the mesonephros (kidney). The feed of this colony of larval relict leopard frogs consisted of a diet rich in oxalate-containing plants (spinach).

matic spread and devastating impact of *B. dendrobatidis* on Panamanian amphibians (Lips et al. 2006) has compelled many parks and facilities to attempt captive breeding programs for neotropical amphibians whose populations are extirpated and faced with extinction in the wild. Feeding habits and prey preferences for many newly captured neotropical amphibians are unknown. Although it is standard practice to supplement the diets of crickets and other live prey items or to dust the live prey items with a complex powder of vitamins and minerals, it is essential for animal caretakers to also consider that most neotropical amphibians originate from forests and soils that are notoriously depleted of minerals. Consequently, many neotropical animals are highly efficient at digesting, absorbing, and storing trace nutrients. The impact of feeding to neotropical amphibians crickets that are heavily dusted with vitamins and trace minerals has yet to be determined, but amphibian care givers should be aware of the potential for vitamin and mineral toxicities.

Diseases Related to Environmental Management

Diseases Related to Improper Husbandry

For both captive and wild amphibian populations, deviations from ideal environmental conditions may be extremely detrimental to health and may relate either directly to development of disease or act as one or more stressors that indirectly predispose animals to diseases. Proper husbandry considerations for captive amphibians must include nutritional needs as well as space, temperature, moisture (humidity, precipitation, standing water), and light requirements, all of which will vary considerably among given species and life stages (Pough 2007, elsewhere in this issue). Dehydration may occur if a habitat is too dry, hyperthermia or hypothermia if it is improperly heated, and respiratory difficulties if premetamorphic stages of some species are held in inadequately oxygenated water.

Gas bubble disease is an environmental disease of fishes and aquatic amphibians that occurs when water is supersaturated with a gas. This disease generally occurs in captive amphibians due to unintentional overaeration of the water. Clinically, gas bubbles may be visible through the skin, particularly in the webs of the feet. Other signs of disease may include lethargy, hemorrhagic or skin ulcers, increased positive buoyancy, and death (Crawshaw 1992). Sequelae of gas bubble disease include necrosis or gangrene of extremities, saprolegniasis of extremities, and septicemia. Treatment is dependent on identification and correction of the underlying cause of supersaturation of the water.

The level of ultraviolet light is an important environmental consideration for amphibians. In free-living populations, elevated levels of ultraviolet-B radiation have been shown to have a detrimental impact on some species of amphibians by decreasing hatch rates, slowing growth and development, and altering behavioral patterns (Blaustein et al. 2003). Disease associated with ultraviolet radiation, although uncommon, is possible among captive amphibians that are maintained under direct sunlight or artificial ultraviolet light. High-level exposure may produce sunburn with potentially lethal secondary skin infections. Clinical signs of sunburn include increased mucous production, erythema, blistering, ulceration, and sloughing of affected skin. Treatment of sunburn involves supportive care, including the use of systemic antibiotics and artificial slime therapeutics (Wright 2001). To prevent further injury, it is essential to re-evaluate light bulbs and lighting regimes, including provision of temperature gradients and proper shading.

Chemical Toxicity

Partly due to the high permeability of their skin, amphibians are very susceptible to toxic insult, and a variety of chemicals may be problematic in wild or captive animals. Nitrogen-based chemicals may act as toxicants in both situations.

Marco et al. (1999) have associated fertilizers and related products that contaminate natural waters via run-off with debilitation, malformations, and death of tadpoles of pond-breeding amphibians.

In closed aquatic culture systems, build-up of nitrogenous waste products such as ammonia and nitrites may be harmful or lethal for aquatic amphibians, much as they are for fishes. Often, disruption of or failure to establish adequate biological filtration will result in problems related to excessive nitrogenous waste build-up. Water quality testing is an essential preventive measure against disease, and routine testing for nitrogenous wastes is an important component. Unionized ammonia levels greater than 0.02 ppm are potentially problematic (Diana et al. 2001). Increased mucous production, altered skin pigmentation, and abnormal swimming/behavior may all be signs of ammonia toxicity. Left unresolved, this syndrome is often lethal. Chronic toxicity may also occur with lower levels of ammonia and may produce immunosuppression and increased susceptibility to infectious diseases (Whitaker 2001). Nitrite toxicity may also occur among amphibians, and we generally advise maintaining nitrite levels below 0.1 ppm. Nitrite toxicity produces a methemoglobinemia and compromises blood oxygen delivery to tissues (Diana et al. 2001). Treatment for nitrogenous waste toxicity involves water changes and correction of any underlying causal factors (e.g., inadequate water filtration, high stocking density). It is also possible to treat amphibians that have methemoglobinemia resulting from nitrite toxicity with aerated baths with methylene blue (Diana et al. 2001).

Various pesticides, either as environmental contaminants that affect wild populations or as chemical treatments used in facilities where amphibians are cultured, may have toxic effects. These chemicals include many classes of potential toxicants such as organophosphates, carbamates, organochlorines, rotenone, and pyrethroids. Effects may vary with dose, species, life stage, and the chemical in question. Generally, the hallmark clinical signs of pesticide toxicity are neurological and potentially include tremors, seizures, reduced righting reflex and locomotor activity, and abnormal posture and behavior. Rotenone toxicity produces signs that are consistent with respiratory distress. High doses and prolonged exposures are often lethal, and pesticide exposures have been implicated in mortality events among wild populations of frogs (Sparling et al. 2001). Blaustein et al. (2003) and Hayes et al. (2006) have also associated sublethal environmental exposures with generalized debilitation, including impaired growth and development and impaired immune function. In addition, investigators including Hayes et al. (2006) and MacKenzie et al. (2003) have linked exposure to a number of pesticides with reproductive impairment, including the development of intersex gonads among amphibians.

Heavy metal toxicity is also problematic among amphibians. Blaustein et al. (2003) have described deleterious effects in association with a number of metals including copper, lead, aluminum, mercury, zinc, cadmium, arsenic,

silver, manganese, molybdenum, and antimony. Of these, metals commonly used in cage enclosures or plumbing are most likely to harm captive specimens. Because of this potential for leeching and toxicity, and as discussed elsewhere in this issue (Browne et al. 2007), we strongly advise against the use of metal in enclosures or plumbing for amphibian maintenance.

Chemicals that are used routinely as cleaning agents or disinfectants in laboratories and animal culture facilities are also potentially lethal to amphibians. Chlorinated cleaning agents such as bleach are highly toxic to many species of amphibians, particularly to aquatic life stages; and even the low-level concentrations usually found in chlorinated tap water may be harmful over time (Diana et al. 2001). Higher levels may be acutely harmful or lethal and may produce hemorrhagic and ulcerative skin lesions and death (Crawshaw 1992). Iodine-based disinfectants, particularly povidone-iodine, may also produce toxicoses that involve generalized debilitation and death (Crawshaw 2003; Diana et al. 2001). Soaps and detergents, if not completely rinsed, have a similar effect on tadpoles. Generally, it is wise to assume that any cleaning agent applied to enclosures or equipment to be used for amphibian husbandry is a potential toxin, which requires vigorous and thorough rinsing before use. In addition, it is equally important to carefully consider any stain or residue that a cleaning agent leaves behind because it may potentially leech the compound and produce toxicity (Diana et al. 2001).

Concluding Thoughts

While this review cannot describe every known disease of amphibians, it does attempt to address the major disease-related issues that will likely be encountered in the laboratory, the classroom, or similar settings involving the use of captive-bred or recently caught wild amphibians. The reader must be aware that countless other infectious and noninfectious diseases may also be problematic in these settings. Furthermore, additional emerging diseases are continually being reported for domestic and wild animals, either as novel pathogens are discovered or as familiar pathogens are observed affecting new species of hosts. As our contact with and understanding of amphibian species continue to increase, so will our awareness of their many and varied diseases. Amphibian medicine is certainly a growing specialty within veterinary medicine. The numbers of veterinarians and scientists specializing in or focusing their work on amphibians and their diseases are increasing. Likewise, the body of available literature including textbooks and peer-reviewed journal articles pertaining to amphibian health and disease is expanding. The reader is urged to become familiar with and take full advantage of these types of resources at their disposal.

The amphibian caretaker must also recognize that good husbandry practices and a sound, thorough knowledge of the species and life stage of interest will go a long way

toward reducing the potential for disease among captive amphibian colonies or specimens. Recognition of the indicators of poor health and the behavioral and physical clinical signs of disease as described throughout this review are critical components of good husbandry practices for the amphibian caretaker.

References

- Annis SL, Dastoor FP, Ziel H, Daszak P, Longcore JE. 2004. A DNA-based assay identifies *Batrachochytrium dendrobatidis* in amphibians. *J Wildl Dis* 40:420-428.
- Barker D, Fitzpatrick MP, Dierenfeld ES. 1998. Nutrient composition of selected whole invertebrates. *Zoo Biol* 17:123-134.
- Berger L, Speare R, Daszak P, Green DE, Cunningham AA, Goggin CL, Slocombe R, Ragan MA, Hyatt AD, McDonald KR, Hines HB, Lips KR, Marantelli G, Parkes H. 1998. Chytridiomycosis causes amphibian mortality associated with population declines in the rainforests of Australia and Central America. *Proc Natl Acad Sci U S A* 95:9031-9036.
- Berger L, Volp K, Mathews S, Speare R, Timms P. 1999. *Chlamydia pneumoniae* in a free-ranging giant barred frog (*Mixophyes iteratus*) from Australia. *J Clin Microbiol* 37:2378-2380.
- Blaustein AR, Hokit DG, O'Hara RK. 1994. Pathogenic fungus contributes to amphibian losses in the Pacific Northwest. *Biol Cons* 67:251-254.
- Blaustein AR, Romansic JM, Kiesecker JM, Hatch AC. 2003. Ultraviolet radiation, toxic chemicals, and amphibian population declines. *Divers Distrib* 9:123-140.
- Blaustein AR, Romansic JM, Scheessele EA, Han BA, Pessier AP, Longcore JE. 2005. Interspecific variation in susceptibility of frog tadpoles to the pathogenic fungus *Batrachochytrium dendrobatidis*. *Cons Biol* 19:1460-1468.
- Blumer C, Zimmermann DR, Weilenmann R, Vaughan L, Pospischil A. 2007. Chlamydiae in free-ranging and captive frogs in Switzerland. *Vet Pathol* 44:144-150.
- Bodetti TJ, Jacobson ER, Wan C, Hafner L, Pospischil A, Rose K, Timms P. 2002. Molecular evidence to support the expansion of the host range of *Chlamydophila pneumoniae* to include reptiles as well as humans, horses, koalas and amphibians. *Syst Appl Microbiol* 25:146-152.
- Bollinger TK, Mao J, Schock D, Brigham RM, Chinchar VG. 1999. Pathology, isolation, and preliminary molecular characterization of a novel iridovirus from tiger salamanders in Saskatchewan. *J Wildl Dis* 35:413-429.
- Boyle DG, Boyle DB, Olsen V, Morgan JAT, Hyatt AD. 2004. Rapid quantitative detection of chytridiomycosis (*Batrachochytrium dendrobatidis*) in amphibian samples using real-time Taqman PCR assay. *Dis Aquat Organ* 60:141-148.
- Browne RK, Odum RA, Herman T, Zippel K. 2007. Facility design and associated services for the study of amphibians. *ILAR J* 48:188-202.
- Browne RK, Scheltinga DM, Pomeroy M, Mahony M. 2002. Testicular myxosporidiosis in anurans, with a description of *Myxobolus fallax* n. sp. *Syst Parasitol* 52:97-110.
- Brunner JL, Richards K, Collins JP. 2005. Dose and host characteristics influence virulence of ranavirus infections. *Oecologia* 144:399-406.
- Burton AN, McClintock J, Rempel JG. 1966. Western equine encephalitis virus in Saskatchewan garter snakes and leopard frogs. *Science* 154:1029-1031.
- Chai N, Deforges L, Sougakoff W, Truffot-Pernot C, DeLuze A, Demeneix B, Clement M, Bomsel MC. 2006. *Mycobacterium szulgai* infection in a captive population of African clawed frogs (*Xenopus tropicalis*). *J Zoo Wildl Med* 37:55-58.
- Cicmanec JL, Ringler DH, Beneke ES. 1973. Spontaneous occurrence and experimental transmission of the fungus, *Fonsecaea pedrosoi*, in the marine toad, *Bufo marinus*. *Lab Anim Sci* 23:43-47.
- Crawshaw G. 2003. Anurans (Anura, Salientia): Frogs, toads. In: Fowler

- ME, Miller RE, eds. Zoo and Wild Animal Medicine. 5th ed. St. Louis: Elsevier Science. p 22-33.
- Crawshaw GJ. 1992. Amphibian medicine. In: Kirk RW, Bonagura JD, Osborne CA, eds. Current Veterinary Therapy. XI. Small Animal Practice. Philadelphia: W.B. Saunders Company. p 1219-1230.
- Cunningham AA, Langton TES, Bennett PM, Lewin JF, Drury SEN, Gough RE, Macgregor SK. 1996a. Pathological and microbiological findings from incidents of unusual mortality of the common frog (*Rana temporaria*). Philo Trans Biol Sci 351:1539-1557.
- Cunningham AA, Sainsbury AW, Cooper JE. 1996b. Diagnosis and treatment of a parasitic dermatitis in a laboratory colony of African clawed frogs (*Xenopus laevis*). Vet Rec 138:640-642.
- Daszak P, Berger L, Cunningham AA, Hyatt AD, Green DE, Speare R. 1999. Emerging infectious diseases and amphibian population declines. Emerg Infect Dis 5:735-748.
- Diana SG, Beasley VB, Wright KM. 2001. Clinical toxicology. In: Wright KM, Whitaker BR, eds. Amphibian Medicine and Captive Husbandry. Malabar FL: Krieger Publishing Company. p 223-232.
- Docherty DE, Meteyer CU, Wang J, Mao J, Case ST, Chinchar VG. 2003. Diagnostic and molecular evaluation of three iridovirus-associated salamander mortality events. J Wildl Dis 39:556-566.
- Duellman WE, Trueb L. 1986. Biology of Amphibians. New York: McGraw-Hill. p 243-244.
- Duncan AE, Garner MM, Bartholomew JL, Reichard TA, Nordhausen RW. 2004. Renal myxosporidiasis in Asian horned frogs (*Megophrys nasuta*). J Zoo Wildl Med 35:381-386.
- Eiras JC. 2005. An overview on the myxosporean parasites in amphibians and reptiles. Acta Parasitol 50:267-275.
- Essbauer S, Ahne W. 2001. Viruses of lower vertebrates. J Vet Med Infect Dis Vet Pub Health 48:401-476.
- Feldman SH, Wimsatt JH, Green DE. 2005. Phylogenetic classification of the frog pathogen *Amphibiotheicum (Dermosporidium) penneri* based on small ribosomal subunit sequencing. J Wildl Dis 41:701-706.
- Fowler ME. 1986. Amphibians. In: Fowler ME, ed. Zoo and Wild Animal Medicine. 2nd ed. Philadelphia: W.B. Saunders Company. p 99-184.
- Frank W. 1975. Mycotic infections in amphibians and reptiles. In: Page LE, ed. Wildlife Diseases. New York: Plenum Press. p 73-87.
- Frost-Mason S, Morrison R, Mason K. 1994. Pigmentation. In: Heatwole H, ed. Amphibian Biology. Vol 1. The Integument. Chipping Norton New South Wales: Surrey Beatty & Sons. p 64-97.
- Frye FL. 1992. Anasarca in an Argentine horned frog *Ceratophrys ornata*. J Sm Exot Anim Med 1:148-149.
- Frye FL, Gillespie DS. 1989. Saprolegniasis in a zoo collection of aquatic amphibians. Orlando: International Colloquium on the Pathology of Reptiles and Amphibians. p 43.
- Gamble KC, Garner MM, West G, Didier ES, Cali A, Alvarado TP. 2005. Kyphosis associated with microsporidial myositis in San Marcos salamanders, *Eurycea nana*. J Herpetol Med Surg 15:14-18.
- Gauthier DT, Rhodes MW, Vogelbein WK, Kator H, Ottinger CA. 2003. Experimental mycobacteriosis in striped bass *Morone saxatilis*. Dis Aquat Organ 54:105-117.
- Gould AR, Hyatt AD, Hengstberger SH, Whittington RJ, Coupar BEH. 1995. A polymerase chain reaction (PCR) to detect epizootic haematopoietic necrosis virus and Bohle iridovirus. Dis Aquat Organ 22:211-215.
- Graczyk TK, Cranfield MR, Bicknese EJ, Wisnieski AP. 1996. Progressive ulcerative dermatitis in a captive, wild-caught, South American giant tree frog (*Phyllomedusa bicolor*) with microsporidial septicemia. J Zoo Wildl Med 27:522-527.
- Granoff A. 1989. Viruses of amphibia: An historical perspective. In: Ahne W, Kurstak E, eds. Viruses of Lower Vertebrates. Heidelberg: Springer-Verlag. p 3-12.
- Green DE. 2001. Pathology of amphibia. In: Wright KM, Whitaker BR, eds. Amphibian Medicine and Captive Husbandry. Malabar FL: Krieger Publishing Company. p 401-485.
- Green DE, Converse KA, Schrader AK. 2002. Epizootiology of sixty-four amphibian morbidity and mortality events in the USA, 1996-2001. Ann N Y Acad Sci 969:323-339.
- Green DE, Harshbarger JC. 2001. Spontaneous neoplasia in amphibia. In: Wright KM, Whitaker BR, eds. Amphibian Medicine and Captive Husbandry. Malabar FL: Krieger Publishing Company. p 335-400.
- Green SE, Bouley DM, Tolwani RJ, Waggie KS, Lifland BD, Otto GM, Ferrell JE Jr. 1999. Identification and management of an outbreak of *Flavobacterium meningosepticum* infection in a colony of South African clawed frogs (*Xenopus laevis*). J Am Vet Med Assoc 214:1833-1838.
- Greer AL, Berrill M, Wilson PJ. 2005. Five amphibian mortality events associated with ranavirus infection in south central Ontario, Canada. Dis Aquat Organ 67:9-14.
- Gruia-Gray J, Desser SS. 1992. Cytopathological observations and epizootiology of frog erythrocytic virus in bullfrogs (*Rana catesbeiana*). J Wildl Dis 28:34-41.
- Hadfield CA, Whitaker BR. 2005. Amphibian emergency medicine and care. Semin Avian Exot Pet Med 14:79-89.
- Hayes RO, Daniels JB, Maxfield HK, Wheeler RE. 1964. Field and laboratory studies on eastern equine encephalitis in warm- and cold-blooded vertebrates. Am J Trop Med Hygiene 13:595-606.
- Hayes TB, Case P, Chui S, Chung D, Haeffele C, Haston K, Lee M, Mai VP, Marjua Y, Parker J, Tsui M. 2006. Pesticide mixtures, endocrine disruption, and amphibian declines: Are we underestimating the impact? Environ Health Perspect 114(Suppl 1):40-50.
- Houlahan JE, Findlay CS, Schmidt BR, Meyers AH, Kuzmin SL. 2000. Quantitative evidence for global amphibian population declines. Nature 404:752-755.
- Hyatt AD, Gould AR, Zupanovic Z, Cunningham AA, Hengstberger S, Whittington RJ, Kattenbelt J, Coupar BEH. 2000. Comparative studies of piscine and amphibian iridoviruses. Arch Virol 145:301-331.
- Iglauer F, Willman F, Hilken G, Huisinga E, Dimigen J. 1997. Anthelmintic treatment to eradicate cutaneous capillariasis in a colony of South African clawed frogs (*Xenopus laevis*). Lab Anim Sci 47:477-482.
- Jacobson E, Origgi F, Heard D, Detrisac C. 2002. Immunohistochemical staining of chlamydial antigen in emerald tree boas (*Corallus caninus*). J Vet Diagn Invest 14:487-494.
- Jancovich JK, Davidson EW, Morado JF, Jacobs BL, Collins JP. 1997. Isolation of a lethal virus from the endangered tiger salamander *Amphispiza tigrinum stebbinsi*. Dis Aquat Organ 31:161-167.
- Johnson AJ, Wellehan JFX. 2005. Amphibian virology. Vet Clin Exot Anim Pract 8:53-65.
- Johnson ML, Berger L, Philips L, Speare R. 2003. Fungicidal effects of chemical disinfectants, UV light, desiccation and heat on the amphibian chytrid *Batrachochytrium dendrobatidis*. Dis Aquat Organ 57:255-260.
- Johnson ML, Speare R. 2005. Possible modes of dissemination of the amphibian chytrid *Batrachochytrium dendrobatidis* in the environment. Dis Aquat Organ 65:181-186.
- Johnson ML, Speare R. 2003. Survival of *Batrachochytrium dendrobatidis* in water: Quarantine and disease control implications. Emerg Infect Dis 9:922-925.
- Johnson PTJ, Lunde KB, Ritchie EG, Launer AE. 1999. The effect of trematode infection on amphibian limb development and survivorship. Science 284:802-804.
- Juopperi T, Karli K, DeVoe R, Grindem CB. 2002. Granulomatous dermatitis in a spadefoot toad (*Scaphiopus holbrookii*). Vet Clin Path 31:137-139.
- Kattenbelt JA, Hyatt AD, Gould AR. 2000. Recovery of ranavirus dsDNA from formalin-fixed archival material. Dis Aquat Organ 39:151-154.
- Kawasaki M. 1972. Hemagglutination inhibiting substances in Japanese encephalitis infected frogs during and after hibernation. Igaku To Seibutsugaku 84:113-116.
- Keller CB, Shilton CM. 2002. The amphibian eye. Vet Clin Exot Anim Pract 5:261-274.
- Kiesecker JM, Belden LK, Shea K, Rubbo MJ. 2004. Amphibian decline and emerging disease. Am Scientist 92:138-147.
- Kiesecker JM, Blaustein AR, Miller CL. 2001. Transfer of a pathogen from fish to amphibians. Cons Biol 15:1064-1070.
- Klenk K, Komar N. 2003. Poor replication of West Nile virus (New York 1999 strain) in three reptiles and one amphibian species. Am J Trop Med Hygiene 69:260-262.

- Kruger KM, Hines HB, Hyatt AD, Boyle DG, Hero JM. 2006. Techniques for detecting chytridiomycosis in wild frogs: Comparing histology with real-time Taqman PCR. *Dis Aquat Organ* 71:141-148.
- Lips KR, Brem F, Brenes R, Reeve JD, Alford RA, Voyles J, Carey C, Livo L, Pessier AP, Collins JP. 2006. Emerging infectious disease and the loss of biodiversity in a neotropical amphibian community. *Proc Natl Acad Sci U S A* 103:3165-3170.
- Longcore JE, Pessier AP, Nichols DK. 1999. *Batrachochytrium dendrobatidis* gen. et sp. nov., a chytrid pathogenic to amphibians. *Mycologia* 91:219-227.
- Lucke B. 1934. A neoplastic disease of the kidney of the frog, *Rana pipiens*. *Am J Cancer* 20:352-379.
- Lunger PD, Darlington RW, Granoff A. 1965. Cell-virus relationships in the Lucke renal adenocarcinoma: An ultrastructural study. *Ann N Y Acad Sci* 186:289-314.
- MacKenzie CA, Berrill M, Metcalfe C, Pauli BD. 2003. Gonadal differentiation in frogs exposed to estrogenic and antiestrogenic compounds. *Environ Toxicol Chem* 22:2466-2475.
- Mao J, Tham TN, Gentry GA, Aubertin A, Chinchar VG. 1996. Cloning, sequence analysis and expression of the major capsid protein of the iridovirus frog virus 3. *Virology* 216:431-436.
- Marco A, Quilchano C, Blaustein AR. 1999. Sensitivity to nitrate and nitrite in pond-breeding amphibians from the Pacific Northwest. *Environ Toxicol Chem* 18:2836-2839.
- Masahito P, Nishioka M, Ueda H, Kato Y, Yamazaki I, Nomura K, Sugano H, Kitagawa T. 1995. Frequent development of pancreatic carcinomas in the *Rana nigromaculata* group. *Cancer Res* 55:3781-3784.
- Maslow JN, Wallace R, Michaela M, Foskett H, Maslow EA, Kiehlbauch JA. 2002. Outbreak of *Mycobacterium marinum* infection among captive snakes and bullfrogs. *Zoo Biol* 21:233-241.
- Mauel MJ, Miller DL, Frazier KS, Hines ME II. 2002. Bacterial pathogens isolated from cultured bullfrogs (*Rana catesbeiana*). *J Vet Diag Invest* 14:431-433.
- Mazzoni R, Cunningham AA, Daszak P, Apolo A, Perdomo E, Speranza G. 2003. Emerging pathogen of wild amphibians in farms (*Rana catesbeiana*) farmed for international trade. *Emerg Infect Dis* 9:995-998.
- Menin M, Giaretta AA. 2003. Predation on foam nests of leptodactylid frogs (Anura:Leptodactylidae) by larvae of *Beckeriella niger* (Diptera: Ephydriidae). *J Zool* 261:239-243.
- Mutschman F. 2004. Pathological changes in African hyperoliid frogs due to a myxosporidian infection with a new species of *Hoferellus* (Myxozoa). *Dis Aquat Organ* 60:215-222.
- Olson ME, Gard S, Brown M, Hampton R, Morck DW. 1992. *Flavobacterium indologenes* infection in leopard frogs. *J Am Vet Med Assoc* 201:1766-1770.
- Parker JM, Mikalian I, Hahn N, Diggs HE. 2002. Clinical diagnosis and treatment of epidermal chytridiomycosis in African clawed frogs (*Xenopus tropicalis*). *Comp Med* 52:265-268.
- Parris MJ, Baud DR. 2004. Interactive effects of a heavy metal and chytridiomycosis on gray treefrog larvae (*Hyla chrysoscelis*). *Copeia* 2004: 344-350.
- Pascolini R, Daszak P, Cunningham AA, Tei S, Vagnetti D, Bucci S, Fagotti A, DiRosa I. 2003. Parasitism by *Dermocystidium ranae* in a population of *Rana esculenta* complex in Central Italy and description of *Amphibiocystidium* n. gen. *Dis Aquat Organ* 56:65-74.
- Patterson-Kane JC, Eckerlin RP, Lyons ET, Jewell MA. 2001. Strongyloidiasis in a Copey's grey tree frog (*Hyla chrysoscelis*). *J Zoo Wildl Med* 32:106-110.
- Pessier AP. 2002. An overview of amphibian skin disease. *Semin Avian Exot Pet Med* 11:162-174.
- Pessier AP, Linn M, Garner MM, Raymond JT, Dierenfeld ES, Graffam W. 2005. Suspected hypovitaminosis A in captive toads (*Bufo* spp.). Proceedings of the AAZV AAWV AZAA/NAG Joint Conference held in Omaha, NE, October 14-21, 2005. p 57.
- Pessier AP, Nichols DK, Longcore JE, Fuller MS. 1999. Cutaneous chytridiomycosis in poison dart frogs (*Dendrobates* spp.) and White's tree frogs (*Litoria caerulea*). *J Vet Diag Invest* 11:194-199.
- Pfeiffer CJ, Nagai T, Fujimura M, Tobe T. 1979. Spontaneous regressive epitheliomas in the Japanese newt *Cynops pyrrhogaster*. *Cancer Res* 39:1904-1910.
- Pough FH. 2007. Amphibian biology and husbandry. *ILAR J* 48:203-213.
- Pounds JA, Crump ML. 1987. Harlequin frogs along a tropical montane stream: Aggregation and the risk of predation by frog-eating flies. *Biotropica* 19:306-309.
- Poynton SL, Whitaker BR. 2001. Protozoa and metazoan infecting amphibians. In: Wright KM, Whitaker BR, eds. *Amphibian Medicine and Captive Husbandry*. Malabar FL: Krieger Publishing Company. p 193-221.
- Reed KD, Ruth GR, Meyer JA, Shukla SK. 2000. *Chlamydia pneumoniae* infection in a breeding colony of African clawed frogs (*Xenopus tropicalis*). *Emerg Infect Dis* 6:196-199.
- Schuetz AW, Selman K, Samson D. 1978. Alterations in growth, function and composition of *Rana pipiens* oocytes and follicles associated with microsporidian parasites. *J Exp Zoo* 204:81-94.
- Shilton CM, Crawshaw GJ, Keller CB, Connelly PW. 2001. Corneal lipid deposition in Cuban tree frogs (*Osteopilus septentrionalis*) and its relationship to serum lipids: An experimental study. *J Zoo Wildl Med* 32:305-319.
- Sladky KK, Norton TM, Loomis MR. 2000. Trombiculid mites (*Hannemania* sp.) in canyon tree frogs (*Hyla arenicolor*). *J Zoo Wildl Med* 31:570-575.
- Smith AW, Anderson MP, Skilling DE, Barlough JE, Ensley PK. 1986. First isolation of calicivirus from amphibians and reptiles. *J Am Vet Med Assoc* 47:1718-1721.
- Smith SA. 2007. Compendium of drugs and compounds used in amphibians. *ILAR J* 48:297-300.
- Sparling DW, Fellers GM, McConnell LL. 2001. Pesticides and amphibian population declines in California, USA. *Environ Tox Chem* 20:1591-1595.
- Speare R, Thomas AD, O'Shea P, Shipton WA. 1994. *Mucor amphibiorum* in the toad, *Bufo marinus*, in Australia. *J Wildl Dis* 30:399-407.
- Speare R, Berger L, O'Shea P, Ladds PW, Thomas AD. 1997. Pathology of mucormycosis of cane toads in Australia. *J Wildl Dis* 33:105-111.
- Speare R, Smith JR. 1992. An iridovirus-like agent isolated from the ornate burrowing frog *Limnodynastes ornatus* in northern Australia. *Dis Aquat Organ* 14:51-57.
- Stacy BA, Parker JM. 2004. Amphibian oncology. *Vet Clin N Am Exot Anim Pract* 7:673-695.
- Stephens LC, Cromeens DM, Robbins VW, Stromberg PC, Jardine JH. 1987. Epidermal capillariasis in South African clawed frogs (*Xenopus laevis*). *Lab Anim Sci* 31:341-344.
- Taylor SK. 2001. Mycoses. In: Wright KM, Whitaker BR, eds. *Amphibian Medicine and Captive Husbandry*. Malabar FL: Krieger Publishing Company. p 181-191.
- Taylor SK, Green DE, Wright KM, Whitaker BR. 2001. Bacterial diseases. In: Wright KM, Whitaker BR, eds. *Amphibian Medicine and Captive Husbandry*. Malabar FL: Krieger Publishing Company. p 159-179.
- Taylor SK, Williams ES, Pier AC, Mills KW, Bock MD. 1999. Mucormycotic dermatitis in captive adult Wyoming toads. *J Wildl Dis* 35: 70-74.
- Tweedell KS. 1989. Herpesviruses: Interaction with frog renal cells. In: Ahne W, Kurstak E, eds. *Viruses of Lower Vertebrates*. Heidelberg: Springer-Verlag. p 13-29.
- Upton SJ, McAllister CT, Trauth SE. 1995. A new species of *Chloromyxum* (Myxozoa: Chloromyxidae) from the gall bladder of *Eurycea* spp. (Caudata: Plethodontidae) in North America. *J Wildl Dis* 31:394-396.
- Weldon C, du Preez LH, Hyatt AD, Muller R, Speare R. 2004. Origin of the amphibian chytrid fungus. *Emerg Infect Dis* 10:2100-2105.
- Whitaker BR. 2001. Water quality. In: Wright KM, Whitaker BR, eds. *Amphibian Medicine and Captive Husbandry*. Malabar FL: Krieger Publishing Company. p 147-157.
- Whitney E, Jamnback H, Means RG, Watthews TH. 1968. Arthropod-borne-virus survey in St. Lawrence County, New York: Arbovirus reactivity in serum from amphibians, reptiles, birds, and mammals. *Am J Trop Med Hygiene* 17:645-650.

- Wilcke BW, Newcomer CE, Anver MR, Simmons JL, Nace GW. 1983. Isolation of *Chlamydia psittaci* from naturally infected African clawed frogs (*Xenopus laevis*). *Infect Immun* 41:789-794.
- Williams RW. 1960. Observations on the life history of *Rhabdias sphaerocephala* Goodey 1924 from *Bufo marinus* L., in the Bermuda Islands. *J Helminthol* 34:93-98.
- Wolf K, Bullock GL, Dunbar CE, Quimby MC. 1969. Tadpole edema virus: Pathogenesis and growth studies and additional sites of virus infected bullfrog tadpoles. In: Mizell MR, ed. *Recent Results in Cancer Research Special Supplement, Biology of Amphibian Tumors*. New York: Springer-Verlag. p 327-336.
- Wolf K, Bullock GL, Dunbar CE, Quimby MC. 1968. Tadpole edema virus: A viscerotropic pathogen for anuran amphibians. *J Infect Dis* 118:253-262.
- Wright KM. 2006. Overview of amphibian medicine. In: Mader DR, ed. *Reptile Medicine and Surgery*. 2nd ed. St. Louis: Saunders, Elsevier. p 941-971.
- Wright KM. 2001. Trauma. In: Wright KM, Whitaker BR, eds. *Amphibian Medicine and Captive Husbandry*. Malabar FL: Krieger Publishing Company. p 233-238.
- Wright KM, Whitaker BR. 2001. Nutritional disorders. In: Wright KM, Whitaker BR, eds. *Amphibian Medicine and Captive Husbandry*. Malabar FL: Krieger Publishing Company. p 73-87.

Web Site References

Additional, color images for this article are posted on the *ILAR e-Journal* web site, www.ilarjournal.com.